

AUDITORY NEUROPATHY SPECTRUM DISORDER IN CHILDREN: ASSOCIATION BETWEEN PERINATAL RISK FACTORS AND RADIOLOGY

Rajinder Mann^{1AB}, Anuradha Sharma^{1EF}, Sanjay Munjal^{1C}, Chirag Ahuja^{2D},
Naresh Panda^{1AE}, Paramjeet Singh^{2BD}

Contributions:
A Study design/planning
B Data collection/entry
C Data analysis/statistics
D Data interpretation
E Preparation of manuscript
F Literature analysis/search
G Funds collection

¹ Department of Otolaryngology (Speech and Hearing Unit), Postgraduate Institute of Medical Education and Research (PGIMER), Chandigarh, India

² Department of Radiodiagnosis and Imaging, PGIMER, Chandigarh, India

Corresponding author: Anuradha Sharma, Department of Otolaryngology (Speech and Hearing Unit), Postgraduate Institute of Medical Education and Research (PGIMER), new OPD, sector 12, Chandigarh 160014, India; email: anuradha2ks@yahoo.com

Abstract

Introduction: Radiological assessment plays a vital role in identifying auditory neuropathy spectrum disorder (ANSD) in children. Identifying the neonatal risk factors and their association with radiological findings might facilitate the management of children with ANSD. The goal of the current work was to investigate the relationship between perinatal risk factors and radiological findings in children with ANSD.

Material and methods: Altogether, 28 children with ANSD aged 1 to 6 were enrolled. Behavioural observation audiometry (BOA), otoacoustic emissions (OAEs), and auditory brainstem responses (ABRs) were conducted. High-resolution computed tomography (CT) and magnetic resonance imaging (MRI) were performed.

Results: There was a statistically significant association between ANSD risk factors – hydrocephalus, preterm birth, hyperbilirubinemia, entry into newborn intensive care, and cerebral palsy – and white matter changes and cerebral/brainstem abnormalities.

Conclusions: In children with ANSD, certain cerebral/brainstem abnormalities and white matter changes were associated with the condition. To minimize the impact of hearing loss, radiological assessments should be conducted on all children having ANSD risk factors.

Key words: magnetic resonance imaging • auditory neuropathy spectrum disorder

ZABURZENIA ZE SPEKTRUM NEUROPATII SŁUCHOWEJ (ANSD): POWIĄZANIA MIĘDZY CZYNNIKAMI RYZYKA A RADIOLOGIĄ

Streszczenie

Wprowadzenie: Ocena radiologiczna jest kluczowa w identyfikacji zaburzeń ze spektrum neuropatii słuchowej (ANSD). Określenie czynników ryzyka i ich związku z wynikami badań radiologicznych mogłoby być pomocne w leczeniu dzieci z ANSD. Celem obecnego badania było ustalenie powiązań między czynnikami ryzyka a wynikami badań radiologicznych u dzieci z zaburzeniami ze spektrum neuropatii słuchowej (ANSD).

Materiał i metody: Łącznie w badaniu uczestniczyło 28 dzieci w wieku od 1 do 6 lat. Wszyscy uczestników przeszli ocenę audiologiczną obejmującą badanie audiometrii obserwacyjnej behawioralnej (BOA), otoemisji akustycznych (OAE) i odpowiedzi słuchowych pnia mózgu (ABR). W celu oceny radiologicznej wykonano badanie tomografii komputerowej wysokiej rozdzielczości i obrazowanie metodą rezonansu magnetycznego.

Wyniki: Wyniki pokazały istnienie statystycznie istotnego związku między nieprawidłowościami w obrębie kresomózgowia/ pnia mózgu a czynnikami ryzyka takimi jak wodogłowie, wcześniactwo, hiperbilirubinemia, pobyt na oddziale intensywnej terapii noworodka i mózgowo-porażenie dziecięce.

Wnioski: Istnieje związek pomiędzy czynnikami ryzyka dla ANSD a nieprawidłowościami w obrębie mózgowia/ pnia mózgu i istoty białej. Z tego powodu u wszystkich pacjentów zgłaszających występowanie czynników ryzyka ANSD należy przeprowadzić ocenę radiologiczną w celu zminimalizowania skutków niedosłuchu.

Słowa kluczowe: obrazowanie metoda rezonansu magnetycznego • zaburzenia ze spektrum neuropatii słuchowej

Introduction

Auditory neuropathy spectrum disorder (ASD) is characterized by the presence of normal otoacoustic emissions (OAE) and cochlear microphonics (CM), with absent or very abnormal auditory brain response (ABR). ANSD is present when patients have normal external hair cell function; however, the eighth cranial nerve that transmits electrical signals to the brain has dyssynchronous responses [1,2]. Various researchers have reported a prevalence of ANSD between 0.5% and 15% [3]. The aetiology of ANSD appears to be multifactorial and can result from various lesions throughout the auditory pathway, from inner hair cells (IHCs) to the cerebral cortex. The lesions may be congenital or acquired. Some possible sites of the lesion include the cochlear inner hair cell, the synapses between the inner hair cells and type I afferents of the auditory division of the eighth cranial nerve, the auditory nerve proper (ganglionopathy, demyelination, or axonopathy), the synapse between the type I afferent axons and cochlear nucleus target cells, the cochlear nucleus itself, and central projections [2,4,5].

Currently, the specific risk factors for ANSD are not clearly understood. While the risk factors associated with sensorineural hearing loss (SNHL) in infants are known, there are no specific risk factors to distinguish ANSD from cochlear hearing loss. Some of the medical risks that have been identified from limited cohort studies are intracranial haemorrhage, asphyxia, Hyperbilirubinemia, prematurity, low birth weight, neonatal ventilation, ototoxic drug exposure, dysmorphic features, Apgar scores, respiratory distress, cytomegalovirus infection, sepsis, meningitis, asphyxia, and family history of hearing loss [6,7]. Rea and Gibson [8] reported hypoxia to be the predominant risk factor in ANSD. They observed that as many as 40% of neonatal intensive care unit (NICU) infants had symptoms similar to ANSD. They pointed out that other researchers also showed that perinatal risk factors such as hyperbilirubinemia, prematurity, hypoxia, and intracranial haemorrhage are linked with ANSD [8]. These factors have also been implicated in other central neurological pathologies. However, there seems to be a paucity of literature for identifying peri and postnatal risk factors more directly related to ANSD.

Evaluation of children with hearing loss requires a multidisciplinary effort that includes audiological assessment, selective use of laboratory testing, referrals among a variety of pediatric specialists, and selective use of radiologic imaging studies. Radiological findings play a huge role in identifying and managing ANSD by giving more options and techniques for detection and treatment. The majority of cochlear and brain abnormalities can be detected through computed tomography (CT-scan) and magnetic resonance imaging (MRI). Limited studies have been done to explore the radiological characteristics and risk factors of ANSD. Identifying the risk factors and their association with radiographic findings would facilitate the management and prognosis of children with ANSD. Hence, in the present study, we aim to find an association between risk factors and radiographic imaging.

Material and methods

Study design

This prospective clinical study included children attending the outpatient department of the Speech and Hearing Unit, Department of Otolaryngology, Head and Neck Surgery of our tertiary care hospital. Only children fulfilling the criteria of bilateral ANSD were enrolled for the study. Informed consent was obtained from all the parents of participants before the assessments. Ethical approval was sought from the Institute's ethics committee prior to the commencement of the study, and all processes contributing to this work comply with the ethical standards of the relevant national and institutional guidelines on human experimentation and with the Helsinki Declaration of 1975, as revised in 2008. Subjects with absent/abnormal ABR with the presence of cochlear microphonics and present OAEs (both TEOAEs and DPOAEs) were diagnosed as having ANSD. However, for confirmation of the diagnosis of ANSD only the presence of cochlear microphonics was considered the key criterion. Only children with bilateral ANSD were enrolled for the study. Of 180 children, 28 were diagnosed with bilateral ANSD; they were between 1 and 6 years of age and came from rural and urban backgrounds. Informed consent was obtained from all the parents of participants before the assessments. Ethical approval was sought from the Institute's ethics committee prior to the commencement of the study.

Procedures

An ENT surgeon carried out a detailed general physical and otorhinolaryngological examination. Thorough pre, peri, and postnatal histories were obtained to assess the risk factors associated with ANSD. Following the demographic assessment, a detailed audiological evaluation was carried out in sound-treated rooms.

Audiological assessment

Behavioural observation audiometry (BOA) was performed with pre-calibrated tools for children below 3 years. A Madsen Orbiter 922 clinical audiometer was used to obtain pure tone thresholds at conventional frequencies from 0.25 to 8 kHz at octave intervals for children between 3 and 6 years old. Standard measures of tympanic membrane mobility (tympanometry) were made along with acoustic reflex thresholds for pure tone stimuli from 0.5 to 4 kHz using an Amplaid A766 middle ear analyser. Acoustic reflexes (ipsilateral and contralateral) were considered absent when there were no responses to test intensities up to 110 dB HL.

DPOAEs and TEOAEs were measured using the Intelligent Hearing Systems (USA) equipment. OAEs were considered present when the SNR was ≥ 6 dB at three consecutive frequencies.

Auditory evoked potentials were measured bilaterally for all the children in the supine position under sedation (Pedicloryl syrup with dosage as recommended by the otolaryngologist) using the Neuro Audio (Russia) software. ABRs were acquired using click stimuli at a rate of

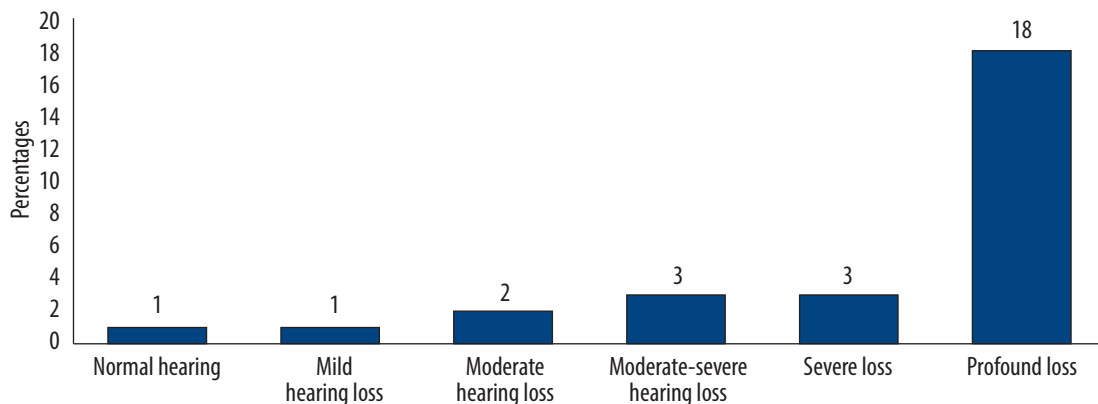


Figure 1. Audiological findings

31.1/s (2048 clicks) at a sound intensity of 90 dBnHL for both ears using alternating as well as rarefaction and condensation polarity. Other parameters for ABR recording were as follows: filter settings between 0.1 to 3 kHz, 2048 clicks for each recording, electrode impedance less than 5 k Ω , electrode montage – non-inverting Cz, inverting M1 and M2, ground Fz. The responses were repeated at each intensity level to ensure reproducibility.

Radiological investigation

The radiological investigation included HRCT-scan and magnetic resonance imaging (MRI).

A HRCT temporal bone scan was performed on a 256-slice Brilliance iCT 3rd generation intelligent CT scanner with slip-ring technology (Philips Healthcare, Philips N.V.). Volumetric CT data were acquired in all cases and were followed by reconstructions in the axial and coronal planes at 1 mm intervals.

MRI evaluations were performed using the institution's custom eighth cranial nerve protocol, performed on either a 1.5 T scanner (Magnetom Aera, Siemens Medical Solutions, Inc., Malvern, PA, USA) or a 3 T scanner (Magnetom Verio, Siemens Medical Solutions, Inc., Malvern, PA, USA). A multichannel head coil was applied through the temporal bones using a SPACE protocol (Sampling Perfection and Application optimised Contrasts using different flip angle Evolution) or with constructive interference in the steady-state (CISS) images. CISS is a gradient-echo MRI sequence used to investigate a wide range of pathologies when routine MRI sequences do not provide the desired anatomic information. The increased sensitivity of the 3D CISS sequence results from the accentuation of the T2 values between cerebrospinal fluid (CSF) and pathological structures. The SPACE sequence is single slab 3D TSE sequence with slab selective, variable excitation pulse. This sequence enables acquisition of high-resolution 3D datasets with contrasts similar to those obtained from 2D T2-weighted, T1-weighted, proton density, and dark fluid protocols at 1.5 T and 3 T within a clinically acceptable timeframe and without SAR limitations. The standard sequence, namely T1 and T2 axial and DWI, was done in all patients. The total scan time for

each study was approximately 20 minutes. The SPACE sequence was reconstructed in the axial plane, and for viewing an oblique sagittal plane oriented perpendicular to the long axis of each IAC was used. All MRI and CT images were reviewed on a clinical Siemens system by two neuroradiologists.

All quantitative measurements were made using the standard protocol. For both MRI and CT examinations, the reviewers subjectively examined the images of temporal bones for cochlear, vestibular, or semi-circular canal abnormalities and enlargement of the endolymphatic duct and sac; the presence, size, and course of the VIII cranial nerve was also recorded. Intracranial MRI images were reviewed for concomitant brain abnormalities, which were subjectively described. Intracranial abnormalities were categorised into prominent temporal horns, CSF and ventricular abnormalities, white matter changes, cerebrum/brainstem abnormalities, Dandy–Walker malformation/cerebellar abnormalities, CSF myelination abnormalities, and ocular abnormalities.

Results

The study sample comprised 28 children (mean age 3.4 years), with 61% males and 39% females.

Audiological findings

The audiological assessment revealed that hearing thresholds ranged from normal hearing to profound hearing loss (WHO classification). The results were that 64%, 11%, 11%, 7%, and 4% had profound, severe, moderately severe, moderate, or mild hearing loss, respectively. One subject had normal hearing. The audiological findings of the subjects diagnosed with ANSD are summarised in **Figure 1**.

Immittance audiometry revealed the presence of Type A tympanograms and the absence of ipsilateral and contralateral reflexes in all subjects. TEOAEs were present in 84% ($n = 47$) ears and absent in 16% ($n = 9$) ears, while DPOAEs were present in 93% ($n = 52$) ears and absent in 7% ($n = 4$) ears. In all cases, ABRs were absent (wave V could not be seen until 99 dBnHL) in both ears and cochlear microphonics were seen on changing the polarity at 90 dBnHL in both ears.

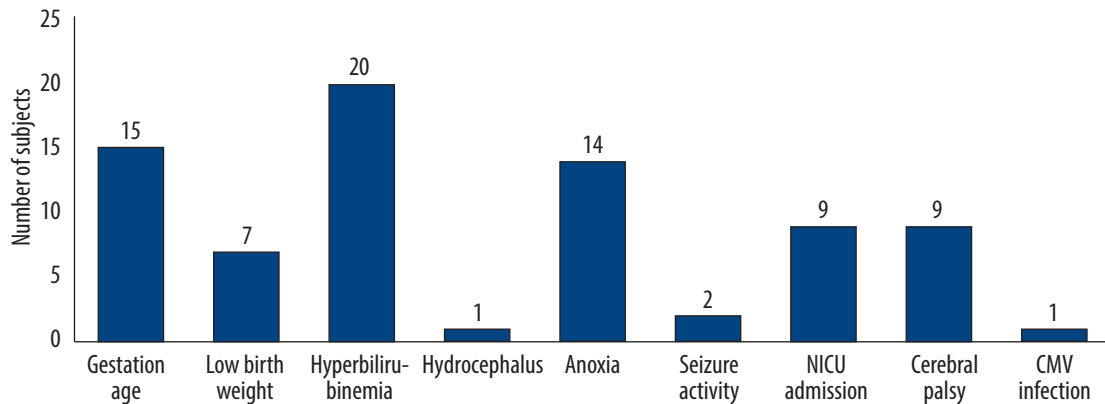


Figure 2. Perinatal history of ANSD subjects

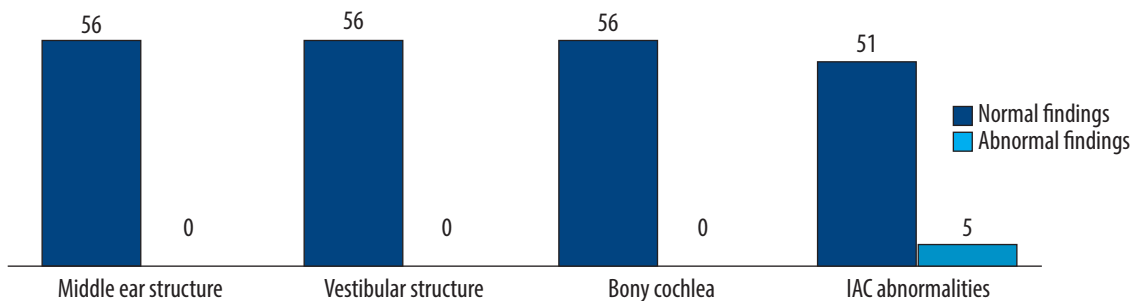


Figure 3. Normal and abnormal CT-scan findings in ANSD patients

Risk factors

A qualitative statistical analysis of risk factors revealed that hyperbilirubinemia ($n = 20$, 71%) was the most common risk factor, followed by preterm birth history ($n = 15$, 54%), birth anoxia ($n = 14$, 50%), NICU admission during the postnatal period ($n = 9$, 32%), history of cerebral palsy ($n = 9$, 32%), and low birth weight ($n = 7$, 25%). A history of seizure activity ($n = 2$, 7%), hydrocephalus ($n = 1$, 4%), and CMV infection ($n = 1$, 4%) were the smallest risk factors. Among 28 subjects, 2 (7%) had no identifiable significant medical history other than a diagnosis of ANSD. There was at least one risk factor in 26 of the 28 subjects. At the same time, 21 demonstrated two or more risk factors in their birth history. **Figure 2** shows these observations.

Radiological findings

CT-scans. There were 28 subjects (56 ears) with confirmed diagnosis of ANSD who underwent a CT-scan. Radiological abnormalities were present in 9% of ears (91% had no abnormalities). Among the ears with abnormal CT scans, all had internal auditory canal abnormalities, i.e. a small internal auditory canal (IAC). Small IACs were found in 3 left ears and 2 right ears. However, normal middle ears, vestibular structures, and bony cochleas were seen in all cases. Results of the HRCT findings in ANSD patients are shown in **Figure 3**.

MRI findings. Among 56 ears (28 subjects), 38 ears had abnormal MRI findings and 18 ears had normal MRIs. There were 38 of 56 ears (68%) whose MRI revealed at least one abnormality, while 24 (43%) had two or more abnormalities.

From MRIs of the inner ear results revealed that, of the 56 ears (28 subjects), 2 ears (4%) had membranous cochlear malformation, 5 ears (9%) had small IAC, and 4 ears (7%) had eighth-nerve abnormalities. Of 5 ears with small IAC, 4 had absent cochlear nerve, and 1 ear had a hypoplastic cochlear nerve. There were 8 nerve abnormalities in individuals with delayed/incomplete myelination. Results of the MRI-Inner ear are shown in **Figure 4**.

A variety of abnormalities were seen on MRI-CNS. The most common abnormalities included white matter changes (57%), cerebrum/brainstem malformation (25%), CSF/ventricular abnormalities (14%), and prominent temporal horn abnormalities (7%). White matter changes included delayed myelination and immaturity of the structures. In one patient periventricular leukomalacia was also noticed. Out of 14 subjects (25%) with cerebrum/brainstem malformation, 4 ears (7%) had cerebellar hypoplasia, 2 ears (4%) had corpus callosum hypoplasia, 2 ears (4%) had cerebral volume loss, and 6 ears (11%) had incomplete/delayed myelination. In terms of CSF/ventricular abnormalities, 4 ears (7%) had nodular heterotopia of the lateral ventricle and 4 ears (7%) had hydrocephalus of the lateral ventricle. Results of the MRI-CNS are shown in **Figure 5**.

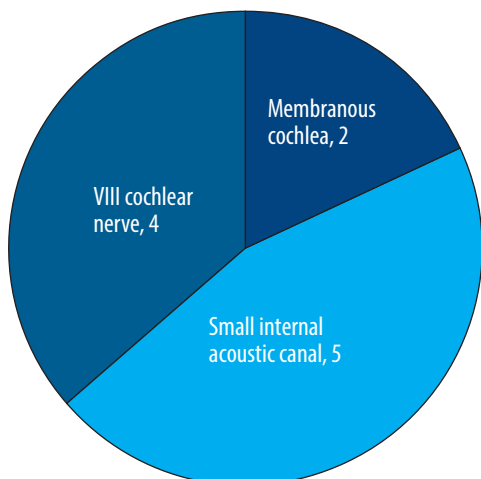


Figure 4. Numbers of abnormalities seen in MRIs of the inner ear

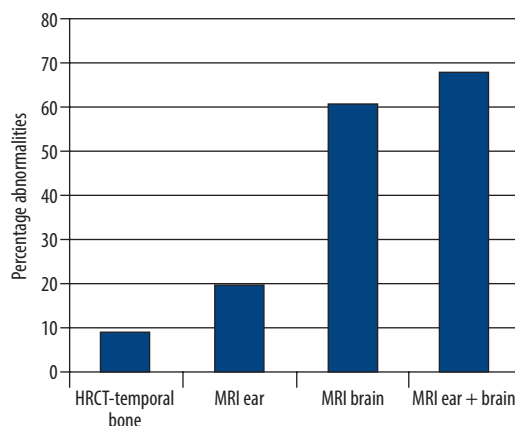


Figure 6. Imaging abnormalities seen in ANSD

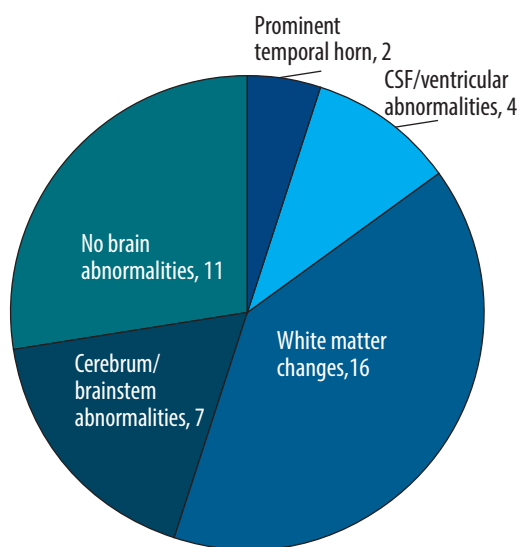


Figure 5. Numbers of abnormalities seen in MRIs of the CNS

In general, abnormalities seen in HRCT were 9%, in MRI-Ear it was 20%, in MRI-Brain it was 61%, and in MRI (Cochlea + CNS) it was 68%. The numbers of CT-scan and MRI-Inner Ear and CNS abnormalities are shown in Figure 6.

Association between risk factors and radiological findings

A Chi-square test was applied to find out the association between ANSD risk factors and radiological findings. Overall, no statistically significant association was found between CT-scan imaging, MRI of the inner ear, and medical history.

However, on MRI-brain imaging statistically significant association was observed between white matter changes and low birth weight ($p = 0.013$) and hyperbilirubinemia ($p = 0.002$). Similarly, a statistically significant association was also observed between cerebrum/brainstem abnormalities and hydrocephalus ($p = 0.013$), preterm birth ($p = 0.005$), hyperbilirubinemia ($p = 0.006$), NICU admission ($p < 0.0005$), and cerebral palsy ($p < 0.0005$). **Table 1**

Table 1. Comparison of risk factors and imaging findings from children with ANSD

	CSF/ventricular abnormalities			White matter changes			Cerebrum/brainstem abnormalities		
	Chi sq	df	Sig	Chi sq	df	Sig	Chi sq	df	Sig
Gestational age	3.063	1	0.080	2.393	1	0.122	7.754	1	0.005*
Low birth weight	3.111	1	0.078	6.222	1	0.013*	0.127	1	0.722
Hyperbilirubinemia	3.777	1	0.053	9.450	1	0.002*	7.467	1	0.006*
Hydrocephalus	0.346	1	0.557	1.556	1	0.212	6.222	1	0.013*
NICU admission	0.218	1	0.640	4.612	1	0.032	13.209	1	<0.0005*
Cerebral palsy	0.218	1	12.444	0.027	1	0.869	13.209	1	<0.0005*

* Statistically significant.

presents the imaging findings and their association with risk factors.

Discussion

The study's findings showed that hyperbilirubinemia, preterm birth history, birth anoxia, NICU admission during the postnatal period, cerebral palsy, low birth weight, history of seizure, hydrocephalus, and history of CMV infection were the risk factors identified with ANSD. Out of 28 subjects, 26 had significant risk factors in conjunction with ANSD, and 2 (7%) had none. This means that ANSD occurs predominantly in conjunction with specific medical risk factors. The present study results align with previous research by Rance and colleagues, which found that 17 of 20 children with ANSD had health concerns in their histories [3]. However, the survey of adult and pediatric cases by Sininger and Oba found that 27% of patients with auditory neuropathy/dysynchrony did not have associated risk factors [9].

Another important finding of the present study was a history of hyperbilirubinemia in 71% of subjects. The current results of a high incidence of hyperbilirubinemia in the ANSD group agree with the findings by Akman and colleagues [10]. They concluded that severe neonatal jaundice might be associated with acute ANSD, a common manifestation of acute bilirubin-induced neurotoxicity in neonates.

Extended NICU stay, hypoxia, prematurity, and hyperbilirubinemia are the other documented risk factors for ANSD. Inner hair cells are more susceptible to damage due to hypoxia than outer hair cells. However, the mechanism of this is not clear.

The other most commonly reported neonatal conditions associated with ANSD in the present study were premature birth history (54%), birth anoxia (50%), and NICU stay (14%). The results of our research are in agreement with the findings of Berg and colleagues, who reported a prevalence of ANSD to be 24.1% from a selected group of NICU infants. They further hypothesized that these infants are exposed to several modalities of treatment and experience specific morbidities that place them at high risk for ANSD [11]. In the present study, 32% of the children also had cerebral palsy, and 25% had low birth weight. These findings follow those of Xoinis et al. [12], who proposed that dexamethasone for severe respiratory illness during a NICU stay might lead to cerebral palsy and ANSD. Some 7% of our subjects had a history of seizures, and 4% had hydrocephalus and CMV infection. Xoinis also observed that 4.2% of the 24 children with ANSD had hydrocephalus [12], findings that are similar to the present study. This intriguing finding strongly suggests an association between various risk factors and the occurrence of ANSD.

The present study also revealed a significant association between radiological findings and risk factors. A statistically significant association was observed between white matter changes and a history of low birth weight and hyperbilirubinemia. Another pronounced finding of the present study was an association between cerebrum/brainstem abnormalities and risk factors such as hydrocephalus, preterm birth, history of hyperbilirubinemia, NICU admission, and

cerebral palsy. Similar studies have been carried out to investigate imaging characteristics in children with ANSD. The authors reported that cochlear dysplasia, brain abnormalities, cochlear nerve deficiency, and prominent temporal horns are the most prevalent findings in ANSD [13].

However, Skranes and coworkers highlighted that adolescents with a very low birth weight had a substantially increased risk of perinatal brain damage due to hemorrhage and periventricular leucomalacia [14]. The injury may affect both white matter tissue and cortical grey matter, which leads to neuro-impairments and disabilities involving motor, perceptual, and cognitive functioning, which tend to evolve during childhood and can persist into adolescence. Furthermore, Yilmaz and colleagues stated that kernicterus' most characteristic neuropathologic lesions are symmetric and highly selective in the basal ganglia [15]. Similar patterns have also been observed [16,17]; Yilmaz stated that the pathologic changes caused by the cytotoxic effect of unconjugated bilirubin consist of discolouration and destruction of affected neurons [15]. Additionally, the neurologic manifestations of kernicterus also include choreoathetosis movements, dystonia, limited eye movements, ANSD, and developmental delay. These neurologic findings mostly involve the basal ganglia. Most of the previous literature has highlighted that risk factors are generally linked with CNS abnormalities [14,18–25].

Our results are in tandem with the previous literature about the possible risk factors for ANSD. When comparing the risk factors of ANSD to radiological findings, we could identify a statistically significant association between medical risk factors and central nervous system abnormalities. We recommend that children diagnosed with ANSD should have radiology imaging as the study of choice for detailed evaluation and management, as early hearing screening of ANSD neonates with risk factors is crucial.

Limitations

The present study had a small sample size, so generalisation of the results to a larger population should be treated with caution. Neurological examination was not carried out on the subjects who participated in the study. The study did not incorporate genetic evaluation to ascertain familial ANSD.

Future directions

The work needs to be replicated on a large sample to better understand the association of risk factors and radiological findings and to prepare better management strategies. In future studies, genetic and neurological evaluations should be included to examine the role of heredity and gain better insight into peripheral neuropathy lesions. A long-term study should be considered examining the audiological changes/radiological changes, speech and language development over time, and functional hearing remission.

Conclusions

Hyperbilirubinemia, Hydrocephalus, preterm birth history, history of NICU admission, and cerebral palsy are risk factors for developing ANSD and are associated with

cerebrum/brainstem abnormalities and white matter changes. This confirms the need for radiological assessment of all subjects reporting with risk factors related to ANSD to minimize the incidence of hearing loss.

Acknowledgements

The research reported here was done under the guidance of Dr Sanjay Munjal. Mr Rajinder Mann carried out data collection under the guidance of Dr Munjal. Dr Chirag

and Dr Parampreet carried out the CT and MRI for all subjects and interpreted the results. We thank all the subjects for their participation.

Declaration

This research did not receive any specific grant from funding agencies in the public, commercial, or not-for-profit sectors. There is no conflict of interest. Data supporting the results will be made available upon request.

References:

- Berlin CI, Hood LJ, Morlet T, Rose K, Brashears S. Auditory neuropathy/dyssynchrony: diagnosis and management. *Mental Retard Devel Disabil Res Reviews* 2003; 9, 225–31.
- Starr A, Picton TW, Sininger Y, Hood LJ, Berlin CI. Auditory neuropathy. *Brain*, 1996; 119: 741–53.
- Rance G, Beer DE, Cone-Wesson B, Shepherd RK, Dowell RC, King AM, et al. Clinical findings for a group of infants and young children with auditory neuropathy. *Ear Hear*, 1999; 21: 238–52.
- Rapin I, Gravel J. Auditory neuropath: physiologic and pathologic evidence calls for more diagnostic specificity. *Int J Pediatr Otorhinolaryngol*, 2003; 67, 707–28.
- Fuchs PA, Glowatzki E, Moser T. The afferent synapse of cochlear hair cells. *Curr Opin Neurobiol*, 2003; 13: 452–8.
- Nikolopoulos TP. Auditory dyssynchrony or auditory neuropathy: understanding the pathophysiology and exploring methods of treatment. *Int J Pediatr Otorhinolaryngol*, 2014; 78(2): 171–3.
- James AL, Osborn HA, Osman H, Papaioannou V, Gordon KA. The limitation of risk factors as a means of prognostication in auditory neuropathy spectrum disorder of perinatal onset. *Int J Pediatr Otorhinolaryngol*, 2020; 135: 110112.
- Rea PA, Gibson WP. Evidence for surviving outer hair cell function in congenitally deaf ears. *Laryngoscope*, 2003; 113(11): 2030–4.
- Sininger YS, Oba S. Patients with auditory neuropathy: who are they and what can they hear? In: Sininger YS, Starr A, editors. *Auditory Neuropathy: A New Perspective on Hearing Disorders*. San Diego: Singular Thomson Learning; 2001, 15–35.
- Akman I, Arika C, Bilgen H, Kalaca S, Ozek E. Transcutaneous measurement of bilirubin by icterometer during phototherapy on a bilibed. *Turkish J Med Sci*, 2000; 32: 165–8.
- Berg AL, Spitzer JB, Towers HM, Bartosiewicz C, Diamond BE. Newborn hearing screening in the NICU: profile of failed auditory brainstem response/passed otoacoustic emission. *Pediatrics*, 2005; 116: 933–8.
- Xoinis K, Weirather Y, Mavoori H, Shaha SH, Iwamoto LM. Extremely low birth weight infants are at high risk for auditory neuropathy. *J Perinatol*, 2007; 27, 718–23.
- Roche JP, Huang BY, Castillo M, Bassim MK, Adunka OF, Buchman CA. Imaging characteristics of children with auditory neuropathy spectrum disorder. *Otol Neurotol*, 2010 Jul; 31(5): 780–8.
- Skranes J, Vangberg TR, Kulseng S, Indredavik MS, Evensen KA, Martinussen M, et al. Clinical findings and white matter abnormalities seen on diffusion tensor imaging in adolescents with very low birth weight. *Brain*, 2007; 130 (Part 3); 654–66.
- Yilmaz Y, Alper G, Kilicoglu G, Celik L, Karadeniz L, Yilmaz-Degirmenci S. Magnetic resonance imaging findings in patients with severe neonatal indirect hyperbilirubinemia. *J Child Neurol*, 2001; 16(6): 452–5.
- Kim MH, Yoon JJ, Sher J, Brown AK. Lack of predictive indices in kernicterus: a comparison of clinical and pathological factors in infants with or without kernicterus. *Pediatrics*, 1980; 66(6): 852–8.
- Turkel SB, Miller CA, Guttenberg ME, Moynes DR, Hodgman JE. A clinical pathologic reappraisal of kernicterus. *Pediatrics*, 1982; 69: 267–72.
- Volpe JJ. Brain injury in the premature infant. *Neuropathology, clinical aspects, pathogenesis, and prevention*. *Clin Perinatol*, 1997; 24(3): 567–87.
- Volpe JJ. Neurobiology of periventricular leukomalacia in the premature infant. *Pediatr Res*, 2001; 50: 553–62.
- Olsen P, Vainionpaa L, Paakko E, Korkman M, Pyhtinen J, Jarvelin MR. Psychological findings in preterm children related to neurologic status and magnetic resonance imaging. *Pediatrics*, 1998; 102: 329–36.
- Inder TE, Huppi PS, Warfield S, Kikinis R, Zientara GP, Barnes PD, et al. Periventricular white matter injury in the premature infant is followed by reduced cerebral cortical grey matter volume at term. *Ann Neurol*, 1999; 46: 755–60.
- Ajayi-Obe M, Saeed N, Cowan FM, Rutherford MA, Edwards AD. Reduced development of cerebral cortex in extremely preterm infants. *Lancet*, 2000; 356: 1162–3.
- Peterson B. Brain imaging studies of the anatomical and functional consequences of preterm birth for human brain development. *Ann NY Acad Sci*, 2003; 1008: 219–37.
- Inder TE, Warfield SK, Wang H, Hüppi PS, Volpe JJ. Abnormal cerebral structure is present at term in premature infants. *Pediatrics*, 2005; 115: 286–94.
- Woodward LJ, Anderson PJ, Austin NC, Howard K, Inder TE. Neonatal MRI to predict neurodevelopmental outcomes in preterm infants. *N Engl J Med*, 2006; 355: 685–94.