

OUTCOMES OF COCHLEAR IMPLANTATION IN PRELINGUAL HEARING IMPAIRED CHILDREN WITH ABNORMAL PREIMPLANTATION IMAGING FINDINGS

Contributions:

A Study design/planning
B Data collection/entry
C Data analysis/statistics
D Data interpretation
E Preparation of manuscript
F Literature analysis/search
G Funds collection

Khairunnisak Mison^{B-D,F}, Tengku Mohamed Izam Tengku Kamalden^{A,E}

Otorhinolaryngology, Hospital Sultan Ismail, Malaysia

Corresponding author: Khairunnisak Mison; Otorhinolaryngology, Hospital Sultan Ismail, Jalan Mutiara Emas Utama, 81100, Johor Bahru, Malaysia;
email: nis875@gmail.com

Abstract

Background: In pediatric patients who are about to undergo cochlear implantation, preimplantation imaging to assess any abnormality in the inner ear or brain is crucial. The literature has shown that inner ear malformation affects auditory and speech development. The objective of this study was to analyze the outcomes of cochlear implant (CI) in children with abnormal imaging findings.

Material and methods: All children had undergone high resolution computed tomography (HRCT) of the temporal bone and magnetic resonance imaging (MRI) of the internal acoustic canal and brain as part of routine preimplantation evaluations. Outcomes of CI were measured using Category of Auditory Performance II (CAP-II) and Meaningful Auditory Integration Scale (MAIS).

Results: There were 25 patients who initially underwent unilateral CI, but 2 patients were excluded, leaving 23 patients in the study. There were 4 patients who had inner ear malformations and another 3 presented with brain findings, while the remaining 16 children had normal findings. In both prelingual hearing impaired children with abnormal and normal imaging findings, there were significant improvements in CAP-II score following CI ($p = 0.020$ and $p = 0.002$, respectively). Similarly, there were statistically significant in MAIS scores in prelingual hearing impaired children with abnormal imaging ($p = 0.017$) as well as with normal imaging ($p = 0.001$). However, when comparing the CAP-II and MAIS scores between children with normal and abnormal imaging, there were no significant differences observed ($p = 0.624$ and $p = 0.376$, respectively).

Conclusions: This study demonstrated that prelingually hearing impaired children with abnormal HRCT and MRI findings gained benefits from CI. Therefore, abnormal imaging findings should not be a limiting factor in CI candidacy.

Key words: computed tomography • magnetic resonance imaging • hearing loss • cochlear implant

WYNIKI WSZCZEPIENIA IMPLANTU ŚLIKAKOWEGO U DZIECI Z NIEDOSŁUCHEM PRELINGWALNYM Z NIEPRAWIDŁOWYMI WYNIKAMI PRZEDOPERACYJNYCH BADAŃ OBRAZOWYCH

Streszczenie

Wprowadzenie: U pacjentów pediatrycznych, którzy mają mieć wszczepiony implant ślimakowy, kluczowe znaczenie ma przedoperacyjne badanie obrazowe aby ocenić anomalie budowy ucha wewnętrznego i mózgu. W literaturze wykazano, że wady rozwojowe ucha wewnętrznego mają wpływ na rozwój słuchowy i mowy. Celem tego badania była analiza wyników wszczepienia implantu ślimakowego (CI) u dzieci z nieprawidłowymi wynikami badań obrazowych.

Material i metoda: Wszystkie dzieci przeszły badanie tomografii komputerowej wysokiej rozdzielczości (HRCT) kości skroniowej i MRI przewodu słuchowego wewnętrznego i mózgu w ramach rutynowego badania przedoperacyjnego. Wyniki wszczepienia CI zmierzono za pomocą skali CAP-II (Category of Auditory Performance II) i skali MAIS (Meaningful Auditory Integration Scale).

Wyniki: Z grupy 25 pacjentów którym wszczepiono jednostronnie CI zostało wyłączonych dwóch pacjentów, pozostawiając w badaniu 23 pacjentów. Czterech z nich miało wady rozwojowe ucha wewnętrznego, trzech kolejnych anomalie w obrębie mózgu, u pozostałych 16 dzieci wyniki badania ucha wewnętrznego i mózgu były w normie. U dzieci z niedosłuchem prelingwalnym zarówno z nieprawidłowymi jak i prawidłowymi wynikami badania obrazowego zanotowano znaczącą poprawę wyników CAP-II po wszczepieniu CI (odpowiednio $p = 0,020$ i $p = 0,002$). Podobnie, zarejestrowano statystycznie istotny wzrost wyniku MAIS u dzieci z niedosłuchem prelingwalnym z nieprawidłowymi wynikami obrazowymi ($p = 0,017$) oraz bez anomalii ($p = 0,001$). Jednak porównanie wyników CAP-II i MAIS pomiędzy grupami dzieci z prawidłowymi i nieprawidłowymi wynikami badań obrazowych nie wykazało istotnych różnic (odpowiednio $p = 0,624$ i $p = 0,376$).

Wnioski: Badanie wykazało, że dzieci z niedosłuchem prelingwalnym z nieprawidłowymi wynikami badań HRCT i MRI uzyskały korzyści z CI. Dlatego też anormalne wyniki badań obrazowych nie powinny stanowić ograniczenia kwalifikacji do wszczepienia CI.

Słowa kluczowe: tomografia komputerowa • obrazowanie metodą rezonansu magnetycznego • niedosłuch • implant ślimakowy

Introduction

Cochlear implant (CI) is an effective treatment for children with prelingual sensorineural hearing loss (SNHL). It is estimated that 20% of children with prelingual SNHL have congenital malformation of the inner ear [1]. Although the incidence of inner ear anomalies and brain lesions in prelingual SNHL is low, imaging is necessary in guiding the surgeon in the selection of CI candidates. Therefore, high resolution computed tomography (HRCT) of the temporal bone and magnetic resonance imaging (MRI) of the internal acoustic canal (IAC) and brain are highly recommended prior to CI.

The literature also mentions that inner ear malformation affects auditory and speech development [2,3]. Papsin et al. reported that children with hypoplastic IAC showed poorer progress than those with other inner ear abnormalities [4]. In addition, children with brain lesions appear to have slower progress post CI [5]. On the contrary, a more recent paper reported that hearing impaired children with inner ear malformation were likely to gain benefit with CI unless there was association with concurrent medical issues such as global developmental delay [6]. Thus, it is important for surgeons and parents to have realistic expectations following CI in findings obtained from radiological imaging.

The objective of this study was to analyze the outcome of CI in children with or without abnormal HRCT and MRI findings by comparing the pre- and post-CI Category of Auditory Performance II (CAP-II) scores and Meaningful Auditory Integration Scale (MAIS).

Material and methods

Participants

This was a 7-year retrospective review on children with prelingual severe to profound SNHL who received a unilateral CI at a single institution between January 2013 and June 2019. The data was retrieved from the Operative Directory Record. The SNHL was confirmed with Auditory Brainstem Response. The inclusion criteria included children who had bilateral severe to profound SNHL with limited benefits from hearing aids. Severe SNHL was defined when the hearing threshold was between 70 to 90 dB, and profound sensorineural HL was defined when the hearing threshold was more than 90 dB.

All of them had undergone HRCT of the temporal bone and MRI of the IAC and brain as part of a routine preimplantation evaluation. The imaging was reported by a paediatric radiologist. Children with any abnormal findings in the brain and inner ear malformation which might contribute as the aetiology for SNHL were recruited. As the CI program was funded by the government, the selection criteria were also stringent: all children who received a CI must use the device for at least 8 hours per day to ensure optimum outcome. The exclusion criteria were children who received bilateral CIs or who were not actively using the implant. Other exclusion criteria included illiterate parents as self-administered assessment tools were used. Post implantation, CI activation were performed 3 to 4 weeks after surgery. The aided thresholds over the CI site were taken at 6 months post implantation.

Outcome measurements

The CAP-II score runs from '0' till '9' [7]. CAP-II is a tool used to assess patient's awareness towards sound. Pre-CI CAP-II scores were evaluated by trained speech and language pathologists who delivered speech rehabilitation to the CI recipients. Post-CI CAP-II improvement was assessed after 6 months. In order to eliminate bias, the assessments were performed by the same speech and language pathologists.

MAIS is a parent-reported questionnaire on a child's ability in terms of sound [8]. MAIS consists of three main domains: confidence, awareness, and identification, with a total score of 40. The MAIS questionnaire was given to parents prior to implantation. Six months post implantation, the parents were given the same assessment tool in order to determine the improvement following CI.

Statistical analysis

Improvements in CAP-II and MAIS scores, before and 6 months following cochlear implantation, were analyzed by using a Wilcoxon signed rank test. A Mann-Whitney *U*-test was performed to analyze the correlation of CAP-II and MAIS among hearing impaired children with normal and abnormal imaging findings. A *p*-value <0.05 was considered statistically significant. Statistical analysis was performed using SPSS version 18.0.

Ethical approval

This study was reviewed and approved by The Ministry of Health Medical Research and Ethics Committee.

Results

Altogether there were 35 CIs performed on prelingual SNHL children at this institution from 2013 till 2019. There were 25 cases (71%) who underwent unilateral CI. Two cases were excluded from the study because one of them had a history of mastoidectomy in other center at an earlier age for mastoiditis, and so the pre-CI HRCT and MRI reports were affected by operative changes. The other patient had complete labyrinthitis ossificans and later underwent an auditory brainstem implant. Among the remaining 23 prelingual SNHL children, 7 of them (30%) fulfilled the criteria for abnormal MRI findings; of the 7, there were 3 (13%) who showed abnormal findings in HRCT of the temporal bone. There were 16 children with normal radiological findings. The characteristics of the prelingual SNHL children are shown in Table 1. In both the prelingual SNHL children with normal and abnormal imaging findings, there were no significant differences in terms of gender, age of implantation, pre-CI hearing thresholds over the implanted and non-implanted side, or post-CI aided threshold.

The details on the 7 prelingual SNHL children with abnormal HRCT and MRI findings are shown in Table 2. Based on HRCT and MRI findings, 4 cases had inner ear malformations while remaining 3 were identified as having abnormal findings in the brain. Inner ear malformations consisted of 2 cases of incomplete partition of the cochlea and 2 cases of cochlear nerve hypoplasia. With regard to

Table 1. Characteristics of 23 prelingual hearing impaired children with normal and abnormal HRCT and MRI findings

Variables	Abnormal HRCT and MRI <i>n</i> = 7	Normal HRCT and MRI <i>n</i> = 16	<i>p</i> -value [†]
Gender (male : female)	2:5	9:7	0.222*
Mean age at implantation (months)	36.0 ± 10.7	42.9 ± 17.1	0.413
Mean pre-CI hearing threshold (CI side) (dB)	105.8 ± 11.4	108.0 ± 8.6	0.871
Mean pre-CI hearing threshold (non CI side) (dB)	102.9 ± 12.3	109.6 ± 10.6	0.154
Mean post-CI aided threshold (dB)	25.1 ± 5.3	33.4 ± 13.2	0.198
Mean pre-CI CAP-II score	2.7 ± 1.5	1.8 ± 1.9	0.803
Mean pre-CI MAIS score	13.9 ± 7.8	14.6 ± 9.3	0.298

* Fisher's Exact test, †Mann–Whitney *U*-test. CAP-II, Category of Auditory Performance; CI, cochlear implant; HRCT, High Resolution Computed Tomography; MAIS, Meaningful Auditory Integration Scale; MRI, magnetic resonance imaging

brain abnormalities, 2 patients had evidence of intrauterine infection which were consistent with cytomegalovirus and rubella infection based on blood investigations, while another patient had features of cerebral demyelination. One patient had global developmental delay. None of the patients developed serious intraoperative complications.

Figure 1 shows the pre- and post-CI CAP-II scores. In prelingual SNHL children with abnormal HRCT and MRI findings (left), there was a significant difference between pre- and post-CI CAP-II score. The mean initial value for pre implantation CAP score in this group was 2.71 ± 1.50 while the 6 months post-CI CAP-II scores was 3.71 ± 1.50 . Similarly, the group of children who had normal HRCT and MRI findings showed significant difference between pre- and post-CI CAP-II scores with mean values of 1.81 ± 1.91 and 3.38 ± 1.63 , respectively. Comparing the post-CI CAP-II score between prelingual SNHL children with abnormal and normal imaging findings, the difference was not statistically significant ($p = 0.624$).

There was a striking difference between pre- and post-CI MAIS score in children with abnormal as well as normal imaging findings as presented in Figure 2. The mean pre-CI MAIS scores in children with abnormal HRCT and MRI was 13.86 ± 7.78 . The post CI score improved to 27.71 ± 10.92 . With regard to children who had normal HRCT and MRI findings, the mean MAIS score improved from 14.56 ± 9.25 before implantation to 23.94 ± 10.23 after implantation. We further analyzed the pre- and post-CI MAIS between children with abnormal and normal imaging findings. There was no significant difference in MAIS score between these two groups ($p = 0.376$).

Discussion

In this study, 30% of children with prelingual hearing impairment who underwent unilateral CI had abnormal imaging findings. This finding was slightly higher than reported in the previous literature which ranges from 15 to 20% [9,10]. This could be because of the small sample size. We found that in all 7 cases with abnormal MRI findings, only 3 abnormal findings were detected in the HRCT of the temporal bone. MRI offers additional information on cochleovestibular bundles and central nervous system pathology [11]. Siu et al. recommend that MRI alone is sufficient as radiological evaluation prior to CI,

and HRCT should only be done if MRI reveals significant abnormality [10]. In contrast, several studies propose that both HRCT of the temporal bone and MRI of the IAC and brain should be routinely implemented prior to CI [12–14]. In our practice, both types of imaging were performed because the findings are complementary to each other in facilitating surgical decision making and planning.

In this study there was no significant difference between pre-CI hearing threshold and post-CI aided threshold for both children with normal and abnormal imaging. This means that the prelingual hearing impaired children with abnormal imaging findings achieved the same comparable auditory gain following CI as children with normal imaging. One of the patients (Case 2) with features of intrauterine infection showed a poor CAP-II score outcome, and this might be attributable to concomitant global developmental delay. It has been shown that approximately 30% of children with SNHL experience other medical disabilities, and so the outcomes of CI are not as good as children without comorbidities [15]. In comparison, another child (Case 3) with similar MRI findings attained a CAP score of 5 post implantation, probably due to the presence of better residual hearing preoperatively.

However, both groups of children with either abnormal or normal imaging illustrated statistically significant difference between pre- and post-CI CAP-II scores. Improvement in the CAP-II among hearing impaired children with inner ear or brain abnormalities has been reported, even though some factors need to be considered such as severe abnormalities seen in imaging [3,16]. Comparing the post-CI CAP-II score between these two groups, there was no significant difference. The results of the present study suggest that there was improvement in CAP-II score regardless of the imaging findings. This finding is contrary to a review in which it was reported that, among children with cochlear or vestibular abnormality, there was a significant association between abnormal inner ears and speech perception post CI. However, early implantation significantly improved the language outcome [17].

In the analysis of MAIS following CI, prelingual hearing impaired children with abnormal and normal imaging showed substantial difference pre- and post-CI. Our result was in accordance with a study by Tay et al. wherein children with isolated inner ear abnormalities showed good

Table 2. Characteristics of 7 prelingually hearing impaired children with abnormal HRCT and MRI findings

Case	Sex	Age at implantation	Hearing threshold (right/left) (dB)	Other medical conditions	Imaging findings	Intraoperative complications	Aided threshold of CI side (dB)	CAP-II score		MAIS	
								Pre	Post	Pre	Post
1	F	4 years 3 months	93.8/120.0	None	HRCT temporal: Normal MRI brain: Foci of hyperintensity in both paraventricular regions at corona radiata, centrum semiovale, and parietal convexities; possible cerebral demyelinating disease	None	Left; 31.3	5	6	9	36
2	M	3 years 5 months	110.0/95.0	Global developmental delay	HRCT temporal: Normal MRI brain: Scattered T2 hyperintensity foci throughout white matter at bilateral cerebral hemisphere suggestive of cerebral intrauterine infection	None	Right; 25.0	1	2	12	20
3	F	2 years 6 months	83.8/110.0	None	HRCT temporal: Normal MRI brain: Bilateral less distinctive cerebral white matter myelination could be due to previous intrauterine infection	None	Left; 20.0	4	5	24	32
4	F	2 years 5 months	93.8/87.5	None	HRCT temporal: Normal MRI brain: Bilateral cochlear nerve hypoplasia	None	Left; 16.3	2	2	25	39
5	F	2 years 9 months	112.5/116.3	None	HRCT temporal: Bilaterally cochleas appear small with inadequate turns MRI brain: Cystic appearance of cochlea with dilated vestibule bilaterally and right cochlear nerve hypoplasia	None	Right; 29.0	1	3	11	25
6	M	1 years 9 months	113.3/110.0	None	HRCT temporal: Bilateral incomplete partition Type I MRI brain: Cystic appearance of cochlea with dilated vestibule bilaterally	None	Right; 28.0	3	4	12	39
7	F	3 years 11 months	102.5/112.5	None	HRCT temporal: Bilateral internal auditory canal narrowed MRI brain: Bilateral cochlear nerve hypoplasia with beaded appearance of bilateral semicircular canals	None	Right; 26.3	3	4	4	10

CAP, Category of Auditory Performance; CI, cochlear implant; HRCT, High Resolution Computed Tomography; MAIS, Meaningful Auditory Integration Scale; MRI, magnetic resonance imaging

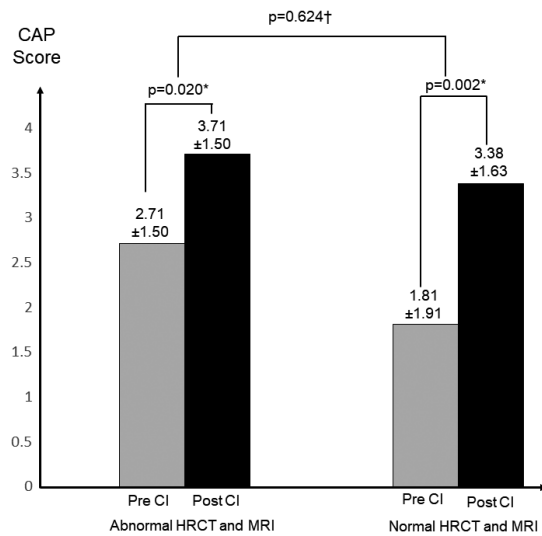


Figure 1. CAP-II score outcomes in prelingually hearing impaired children. (*Wilcoxon Signed Rank test; †Mann-Whitney *U*-test; CAP, Category of Auditory Performance; CI, cochlear implant; HRCT, High Resolution Computed Tomography; MRI, magnetic resonance imaging)

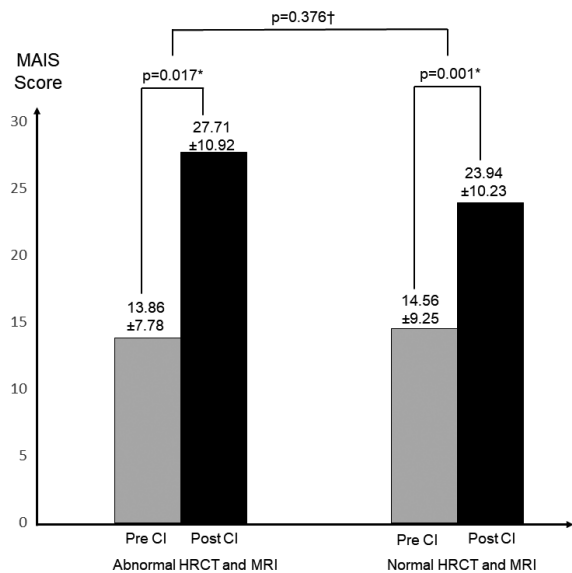


Figure 2. MAIS score outcomes in prelingually hearing impaired children. Abbreviations as per Figure 1

MAIS outcomes with CI [6]. Another study revealed that the overall MAIS outcome improved following CI, even though the presence of a common cavity of the cochlea and narrow IAC are associated with poorer prognostic factors compared to CI recipients with normal radiological findings [3].

This study has a few limitations. First, it was done retrospectively with a small sample size. Second, the HRCT and MRI findings need to be further stratified into specific inner ear and brain lesions in order to understand the outcome of each pathology in detail. Therefore, a prospective study with a larger cohort and perhaps a multi-center involvement will provide a more definite conclusion in the future.

Conclusion

This study has demonstrated that prelingual hearing impaired children with abnormal imaging findings showed significant improvement in CAP-II and MAIS scores following CI, an improvement that was comparable to children with normal imaging findings. Therefore, the presence

of abnormal HRCT and MRI findings should not be limiting factors for CI as it seems that these children gain benefit from CI too.

Acknowledgement

The authors thank the Director-General of Health Malaysia, Ministry of Health, for permission to publish this paper. Special thanks to Dr Muhammad Syafiq Hilmi bin Musa, Dr Noor Hanisah Sulaiman, Ms Chong Lun Cheh (speech and language therapist), and Mr Zulkarnain Azali (audiologist) from the Department of Otorhinolaryngology, Hospital Sultan Ismail, Johor, for the data collection.

Conflict of interest

The authors have no potential conflicts of interest to disclose.

Source of funding

This research did not receive any specific grant from funding agencies in the public, commercial, or not-for-profit sectors.

References

1. Simons JP, Healy GB, Bluestone CD (eds). *Bluestone and Stool's Paediatric Otolaryngology: Congenital inner ear anomalies*. USA, People's Medical Publishing House, 2014.
2. Swami H, James E, Sabirgirish K et al. A study to determine factors influencing outcomes of paediatric cochlear implants. *Med J Armed Forces India*, 2013; 69(4): 366–8.
3. Busi M, Rosignoli M, Castiglione A et al. Cochlear implant outcomes and genetic mutations in children with ear and brain anomalies. *BioMed Res Int*, 2015; 2015: 696281.
4. Papsin BC. Cochlear implantation in children with anomalous cochleovestibular anatomy. *Laryngoscope*, 2009; 115: S106.
5. Moon IJ, Kim EY, Park GY et al. The clinical significance of pre-operative brain magnetic resonance imaging in paediatric cochlear implant recipients. *Audiol Neurotol*, 2012; 17(6): 373–80.
6. Tay SY, Anicette R, Tan KKH. A ten-year review of audiological performance in children with inner ear abnormalities after cochlear implantation in Singapore. *Int J Otolaryngol*, 2019: 6483714.
7. Archbold S, Lutman ME, Marshall DH. Categories of auditory performance. *Ann Otol Rhinol Laryngol Suppl*, 1995; 166: 312–4.

8. Robbins AM, Renshaw JJ, Berry SW. Evaluating meaningful auditory integration in profoundly hearing-impaired children. *Am J Otolaryngol*, 1991; 12: 144–50.
9. Xu XQ, Wu FY, Hu H et al. Incidence of brain abnormalities detected on preoperative brain MR imaging and their effect on the outcome of cochlear implantation in children with sensorineural hearing loss. *Int J Biomed Imaging*, 2015; 2015: 275786.
10. Siu JM, Blaser SI, Gordon KA et al. Efficacy of a selective imaging paradigm prior to paediatric cochlear implantation. *Laryngoscope*, 2019; 129(11): 2627–33.
11. Young JY, Ryan ME, Young NM. Preoperative imaging sensorineural hearing loss in paediatric candidates for cochlear implantation. *RadioGraphics*, 2014; 34(5): e133–e149.
12. Hanafi MG, Saki N, Shanehsaz F. Diagnostic value of CT and MRI of temporal bone in cochlear implantation candidates. *Int J Paediatr*, 2019; 7(7): 9693–700.
13. Digge P, Solanki RN, Shah DC et al. Imaging modality of choice for pre-operative cochlear imaging: HRCT vs MRI temporal bone. *J Clin Diagn Res*, 2016; 10(10): TC01–TC04.
14. Taha T, Eahba S, Ibrahim AS et al. Cochlear implant tailored imaging protocol: what clinicians need to know. *Egypt J Radiol Nucl Med*, 2015; 46(1): 33–43.
15. Vincenti V, Bacciu A, Guida M et al. Paediatric cochlear implantation: an update. *Ital J Paediatr*, 2014; 40: 72.
16. Han JJ, Bae YJ, Song SK et al. Prediction of the outcome of cochlear implantation in the patients with congenital cytomegalovirus infection based on magnetic resonance imaging characteristics. *J Clin Med*, 2019; 8(2): 136.
17. Dettmann S, Sadeghi-Barzalighi A, Ambett R et al. Cochlear implants in forty-eight children with cochlear and/or vestibular abnormality. *Audiol Neurotol*, 2011; 16: 222–32.