

AUDITORY EVALUATION IN A CASE OF HEARING LOSS IN AN INFANT WITH CONGENITAL ZIKA SYNDROME (CZS)

Contributions:

A Study design/planning
B Data collection/entry
C Data analysis/statistics
D Data interpretation
E Preparation of manuscript
F Literature analysis/search
G Funds collection

Milaine Dominici Sanfins^{1,2,A-G}, Lavinia Brandão^{2,B},
Piotr Henryk Skarzynski^{3,4,5,D}, Silvana Griz^{2,6,B}, Adriana Melo^{2,E}

¹ Electrophysiology, Advanced Electrophysiology and Neuroaudiology Center, Brazil

² Audiology, Instituto de Pesquisa Professor Joaquim Amorim Neto (IPESQ), Brazil

³ Audiology, Institute of Physiology and Pathology of Hearing, Poland

⁴ Audiology, Department of Heart Failure and Cardiac Rehabilitation, Poland

⁵ ENT, Institute of Sensory Organs, Poland

⁶ Audiology, Universidade Federal de Pernambuco – UFPE, Brazil

Corresponding author: Milaine Dominici Sanfins; Electrophysiology, Advanced Electrophysiology and Neuroaudiology Center, Avenida Jacutinga, 220- apto 12, 04515-030, São Paulo, Brazil; email: msanfins@uol.com.br; Phone: +5511990033092

Abstract

Background: The Zika virus (ZIKV) was detected in Brazil in 2014. At the end of 2015 microcephaly was the first distinctive sign. By 2016, the first two cases of congenital Zika had been described, with a strong correlation between the virus and microcephaly.

Case report: A male infant was born at 32 weeks gestation, weight 1,750 grams, cranial perimeter 26 cm. He remained in intensive care for 5 days for neonatal seizures, required oxygen therapy, and had early sepsis. After 11 days in hospital a diagnosis of microcephaly was made. At 12 months, hydrocephalus was identified by computed tomography, with calcification foci in the subcortical region, basal nuclei, cerebellum, and brainstem. These characteristics are typical of congenital Zika syndrome (CZS). Audiological tests were done: immittanceometry (tympanometry and acoustic reflex), transient evoked otoacoustic emission (TEOAE), distortion product otoacoustic emission (DPOAE), click ABR, and frequency following response (FFR). In patients with ZIKV, radiological findings show distinctive calcifications at the gray-white matter junction and degrees of delayed cortical development. The findings here of no acoustic reflex and a reduction in otoacoustic emissions in both ears is a preliminary indication of outer hair cell involvement that could later lead to communication deficits. ABR responses showed hearing pathway impairment in both ears up to the brainstem, and diminished FFR responses point to possible difficulties in speech perception. The present case study adds to our knowledge of the effect of CZS on the auditory system and strengthens the recommendation that ZIKV be included as an indicator for risk of hearing loss.

Key words: electrophysiology • hearing loss • Zika virus • microencephaly

OCENA SŁUCHOWA PRZYPADKU NIEDOSŁUCHU U DZIECKA Z WRODZONYM ZESPOŁEM ZIKA (CZS)

Streszczenie

Wprowadzenie: Wirus Zika (ZIKV) został wykryty w Brazylii w 2014 r. Pod koniec 2015 r. pierwszym wyróżniającym się objawem było małowłowie. Do końca 2016 r. opisane zostały dwa pierwsze przypadki wrodzonego zakażenia wirusem Zika, z silną korelacją pomiędzy obecnością wirusa a małowłowiem.

Opis przypadku: Dziecko płci męskiej urodzone w 32 tygodniu ciąży, waga urodzeniowa 1750 gram, obwód czaszki 26 cm. Chłopiec przebywał na oddziale intensywnej terapii przez 5 dni z powodu drgawek noworodkowych, wymagał terapii tlenowej i miał wczesną sepsę. Po 11 dniach hospitalizacji zdiagnozowane zostało małowłowie. W 12 miesiącu życia, w badaniu tomografii komputerowej wykryto wodogłowie z ogniskowymi zwapnieniami w obszarze podkorowym, jąder podstawnych, mózdzku i pnia mózgu. Są to oznaki typowe dla wrodzonego zespołu Zika (CZS). Wykonano badania audiologiczne: pomiar imitacji (tympanometria i badanie odruchu mięśnia strzemiączkowego), badanie emisji otoakustycznych wywołanych trzaskiem (TEOAE), emisji otoakustycznych produktów zniekształceń nieliniowych (DPOAE), badanie ABR dla trzasku i rejestrację odpowiedzi podążających za częstotliwością (frequency following response FFR). U pacjentów z ZIKV badania radiologiczne wykazują charakterystyczne zwapnienia na granicy między istotą białą i szarą oraz różne stopnie opóźnionego rozwoju kory. Wykryty w badaniach brak odruchu mięśnia strzemiączkowego i zmniejszenie emisji otoakustycznych w obojgu uszu są pierwszą oznaką zaangażowania zewnętrznych komórek słuchowych które w późniejszym okresie może prowadzić do zaburzeń komunikacji. Odpowiedzi ABR świadczą o obustronnym upośledzeniu drogi słuchowej aż do poziomu pnia mózgu, a zmniejszone odpowiedzi FFR wskazują na możliwość wystąpienia zaburzeń percepcji mowy. Prezentowane studium przypadku wzbogaca naszą wiedzę na temat wpływu CZS na układ słuchowy i wzmacnia zalecenie, by traktować ZIKV jako czynnik zwiększonego ryzyka wystąpienia niedosłuchu.

Słowa kluczowe: elektrofizjologia • niedosłuch • wirus Zika • małowłowie

Introduction

The Zika virus (ZIKV) was detected in Brazil in 2014 with most cases reported in the Northeast Region [1]. Microcephaly was the first sign to be highlighted at the end of 2015. By 2016 the first two cases of congenital Zika had been described [2], with a strong correlation between the virus and microcephaly [3]. According to Araújo [4], ZIKV infection is considered a possible cause of the microcephaly (defined as a neonatal head circumference at least 2 SD smaller than the average for their sex and gestational age [5]). Ensuing studies have concluded that microcephaly is only the main symptom, and Congenital Zika Syndrome (CZS) is now characterized as an association of cranial anomalies (microcephaly, subcortical and basal calcification, developmental cortical changes, *ex vacuo* ventriculomegaly, hydrocephalus, cerebellar vermis hypoplasia, and brainstem hypoplasia, among others) [6,7], and extracranial anomalies (arthrogryposis, auditory deficit, visual deficit, dysphagia, delay in motor and cognitive development, and others) [8–10].

Recognizing the symptoms of ZIKV is not easy, since many infected individuals are asymptomatic [11]. When symptoms do appear, they are related to complaints of headache, arthralgia, pruritus, maculopapular eruption, and conjunctivitis [12,13]. The most accurate diagnosis of ZIKV is through real-time polymerase chain reaction (RT-PCR) of body fluids such as serum, saliva, or urine in the first few days of acute infection [14]. Amniotic fluid can also be tested.

In terms of the effects of the virus on the peripheral and central auditory nervous system, there is still much to be learnt. As to hearing problems, there are reports of hearing loss, tinnitus, and dizziness, but it is still too early to say whether these changes are temporary or permanent.

Although the scientific literature already contains articles addressing the effects of ZIKV on the auditory system, there are still many gaps that need to be filled, even just alerting the medical community on the subject. The aim of this study was to describe audiological findings in an infant with CZS.

Case report

This study was approved by the Ethics Research Committee under protocol number 52888616.4.0000.5693. Audiological data were collected in October 2018. Informed consent for research was obtained from the parents after an explanation of the nature, purpose, and expected results of the study.

Maternal history. At 3 months of pregnancy the mother developed red spots all over her body, accompanied by a urinary infection and anemia. At the time she did not consult with a medical practitioner to investigate the disease.

Neonatal history. The infant was born at 32 weeks gestational age, weight 1,750 grams, cranial perimeter of 26 cm, Apgar at 1 minute of 8 and at 5 minutes of 9. The STORCH test (syphilis, toxoplasmosis, rubella, cytomegalovirus, and

herpes) was negative. The infant remained in the intensive care unit for 5 days for neonatal seizures, required oxygen therapy, and had early (<48 hours) sepsis. He stayed in hospital for 11 days and was diagnosed as having congenital microcephaly. Around 12 months of life, hydrocephalus was identified by computed tomography.

Current condition. Neuropsychomotor development shows absence of cervical control and delay of language development (although there is no babbling). Currently, he has a major visual deficit, convulsions, limb stiffness, spasms, and needs to be fed via gastrostomy.

Radiological findings. Agyria associated with a major reduction in cerebral volume with severe compensatory ventriculomegalia, agenesis of the corpus callosum, and enlargement of the posterior fossa associated with severe hypoplasia of cerebellum and cerebellar vermis. We also observed a hypoplastic and discretely segmented cerebral trunk. Calcification foci were observed in the subcortical region, nuclei of the base, cerebellum, and brainstem (Figure 1).

The child was referred for audiological evaluation at age 23 months and the following procedures were performed.

Tympanometry and acoustic reflex. Tympanometry was performed with a 226 Hz probe tone. Testing for ipsilateral and contralateral acoustic reflexes was done with sound frequencies of 500, 1000, 2000, and 4000 Hz. The subject presented maximum compliance at around 0 daPa and had an equivalent volume of 0.3–1.3 mL according to the proposal of Jerger (1970) [15]. The presence of a type A tympanometric curve with an absence of ipsilateral and contralateral acoustic reflexes was found in both ears.

Transient evoked otoacoustic emissions. TEOAEs were recorded in both ears with a click stimulus of 83 dB SPL. A pass result required reproducibility of $\geq 70\%$ and a signal-to-noise ratio ≥ 6 dB in at least three frequency bands. There was no response in either ear (Table 1).

Distortion product otoacoustic emissions (DPOAEs). Frequencies f1 and f2 were presented simultaneously at intensities of 65 and 55 dB, respectively, with $f2/f1 = 1.22$. A pass result required a signal-to-noise ratio of ≥ 6 dB over at least three frequencies. There were no responses in either ear (Table 2).

Click ABR and FFR evaluation. Surface electrodes were placed according to the 10–20 International System: active electrode at the apex (Cz), reference electrode on the ipsilateral mastoid, and ground electrode on the contralateral mastoid [16]. The parameters used are shown in Table 3.

Auditory brainstem response (ABR). Waves I, III, and V and the inter-peak intervals I–III, III–V, and I–V were analysed. For all identified peaks, the latency in ms and amplitude in μV were recorded. The amplitude was measured as the difference between the amplitude of the first peak and the subsequent trough. The results were compared with the normal values proposed by the Bio-logic Navigator Pro [17,18]. Figure 2 shows the result with the subject, and it can be seen that in the left ear there are no responses to 95 and 80 dB nHL stimuli, while in the right ear only responses to

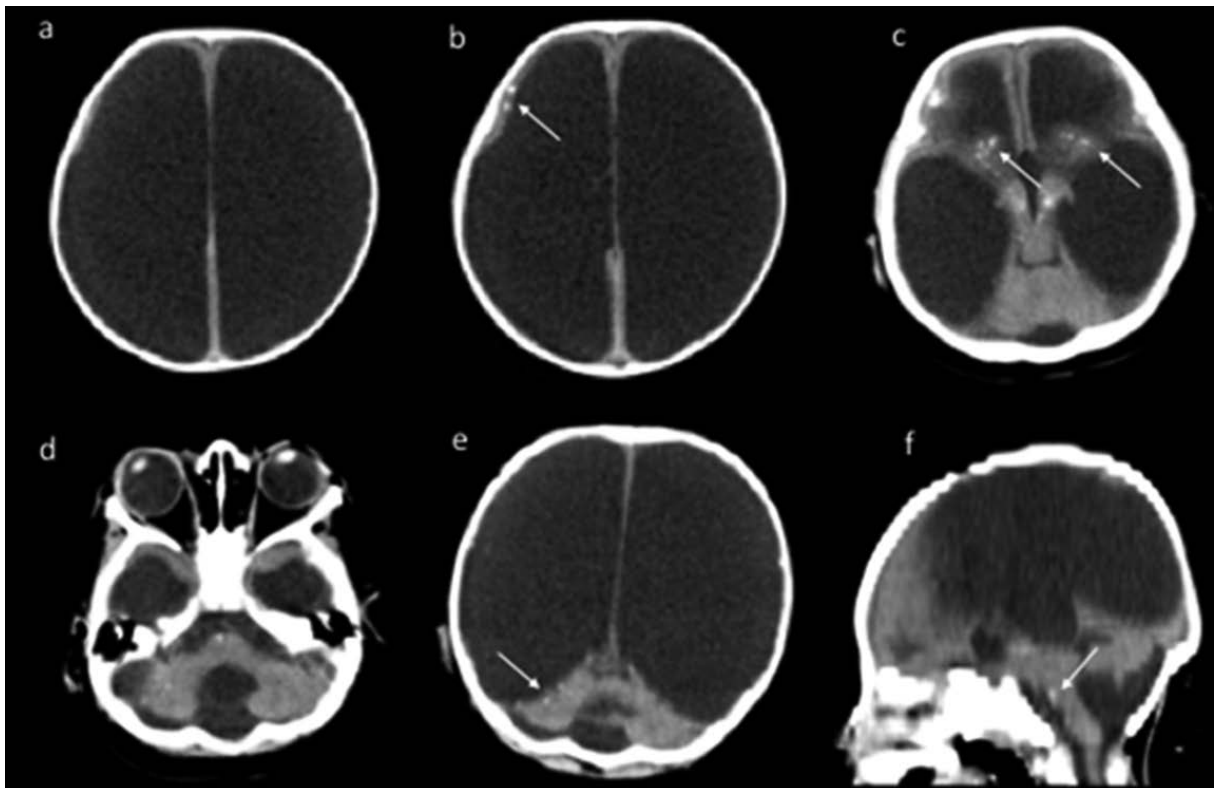


Figure 1. *a)* major ventriculomegaly associated with severe reduction of cerebral parenchyma and agitation. *b)* subcortical calcifications (arrow). *c)* calcifications in nuclei of the base (arrows). *d)* cerebellar vermis hypoplasia, hypoplastic cerebellum. *e)* calcifications in the cerebellum (arrow). *f)* hypoplastic brainstem, cerebellar vermis hypoplasia, and calcifications in the brainstem (arrow)

Table 1. TEOAEs responses in the subject at age 23 months

	Stability (%)	Frequency									
		1000 Hz		1500 Hz		2000 Hz		3000 Hz		4000 Hz	
		SNR (dB)	N	SNR (dB)	N	SNR (dB)	N	SNR (dB)	N	SNR (dB)	N
Right ear	99.7	-23.0	-4.6	-21.3	1.2	-15.0	-3.4	-13.0	-0.5	-11.5	-3.6
Left ear	99.9	-19.1	-1.2	-19.8	-3.2	-18.0	-2.1	-15.7	-1.8	-15.5	-2.4

Key: SNR, signal-to-noise ratio; dB, decibel; N, noise

Table 2. DPOAE responses in the subject at age 23 months

	Stability (%)	Frequency (GM)									
		1818 Hz		2542 Hz		3616 Hz		5083 Hz		7206 Hz	
		SNR (dB)	N	SNR (dB)	N	SNR (dB)	N	SNR (dB)	N	SNR (dB)	N
Right ear	99.7	-15.00	1.0	-13.62	1.2	-12.00	-0.5	-10.00	-1.00	-15.57	1
Left ear	99.9	-10.0	-2.5	-14.38	-0.5	-8.00	1.0	-9.98	1.2	-12.58	-1.2

Key: GM, geometric mean; SNR, signal-to-noise ratio; dB, decibel; N, noise

Table 3. Parameters for acquiring Click ABR and FFR

Parameter	Click ABR	FFR
Equipment	Biologic Navigator Pro	Biologic Navigator Pro
Stimulated ear	RE/LE	RE
Type of stimulus	Click	Speech
Duration of stimulus	0.1 msec	40 msec
Polarity of stimulus	Rarefaction	Alternate
Intensity of stimulus	variable	80 SPL
Rate of stimuli	19.3/sec	10.9/sec
Number of scans	2000	3000
Replication	2 collections of 2000 stimuli	2 collections of 3000 stimuli
Filter	100–1500 Hz	100–2000 Hz
Window	10.66 ms	85.33 ms
Transducer	Insert (ER-3A; Natus Medical)	Insert (ER-3A; Natus Medical)

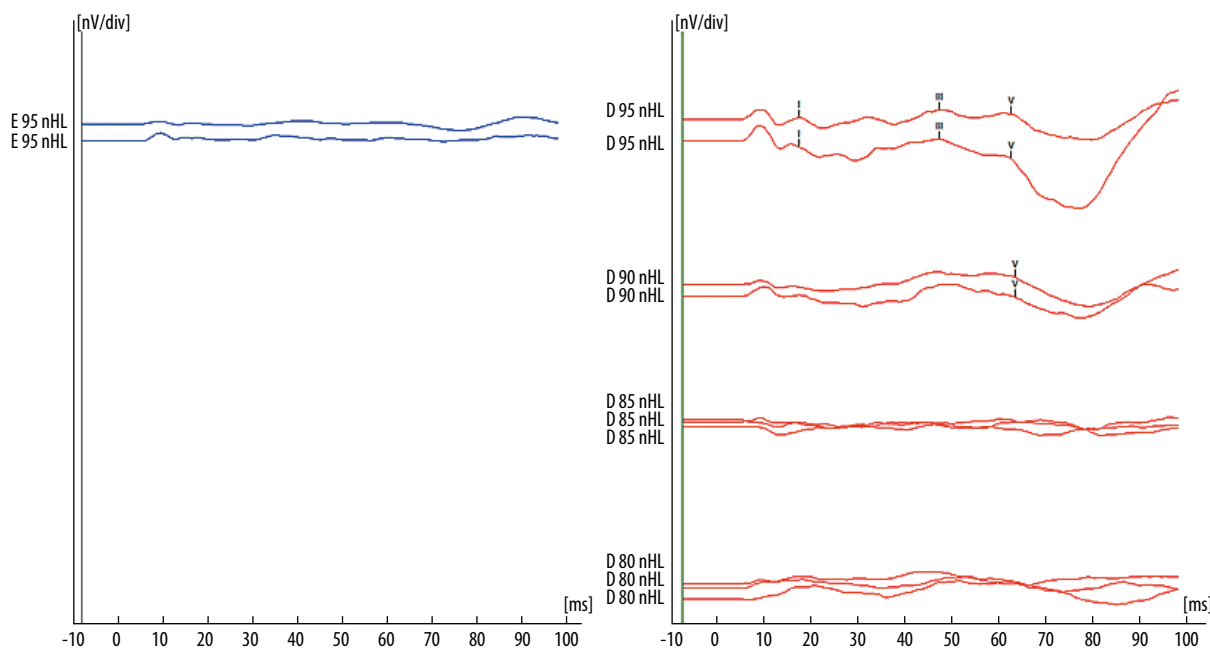


Figure 2. ABR click responses in the subject at age 23 months (blue, left ear; red, right ear).

95 and 90 dB nHL could be observed. The 90 dB nHL trace shows the presence of wave V with an absolute latency of 6.32 ms. At 95 dB nHL, there are waves I, III, and V with latencies of 1.70; 4.70, and 6.24 ms, respectively; the inter-peak intervals are 3.00 ms (I–III), 1.54 ms (III–V), and 4.54 ms (I–V).

Frequency following response (FFR). The analysis was performed in two ways.

Time waveform. Latency and amplitude of the seven waves (V, A, C, D, E, F, and O) elicited by the syllable /da/ were recorded based on the criteria of previous published studies [19–25]. In addition, the slope of the VA complex was also measured (–0.05 $\mu\text{V}/\text{ms}$), a parameter which is related to the temporal synchronization of the response generators [26], as well as the area of the VA complex (0.109 $\mu\text{V} \times \text{ms}$), which is related to the amount of activity that contributes to the wave [26]. There was a clear difference in amplitude between the normative wave and the patient’s response

(Figure 3). In addition, the patient’s latencies appear to be delayed in comparison with the normative wave.

Correlation/Correlogram. This function calculates the stimulus-to-response relationship given in the BioMARK Brainstem Toolbox software. The acoustic features of the stimulus (spectral and temporal) are represented in the FFR evaluation, making it possible to perform a correlation stimulus–response analysis. In the present study, the correlogram between the stimulus and the response gave a figure of 0.18 (asterisks shown at correlation maximum), demonstrating that there is a weak electrophysiological response for speech. In other words, there is an important difference (deficient activation neurons) between the applied stimulus and the response from the infant (Figure 4).

Discussion

According to the Joint Committee on Infant Hearing (JCIH) [27], infants who present hearing impairment risk indicators

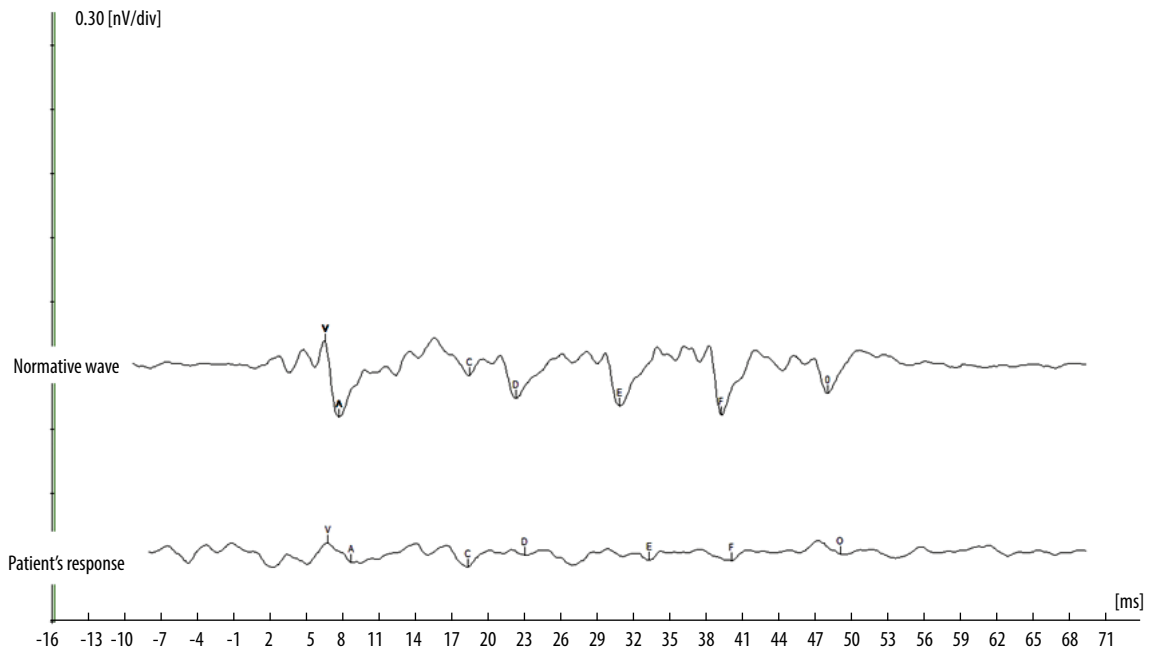


Figure 3. FFR responses in the child at age of 23 months. The following values of latency and amplitude were identified: wave A: 6.78 ms / 0.05 μ V; wave V: 8.7 ms / -0.04μ V; wave C: 18.37 ms / -0.07μ V; wave D: 23.03 ms / -0.01μ V; wave E: 33.28 ms / -0.03μ V; wave F: 40.11 ms / -0.03μ V; wave O: 49.11 ms / -0.01μ V

in which congenital infections are involved should be monitored for changes in the peripheral and central auditory nervous systems. Auditory alterations can cause significant impairments to speech, language, and learning.

Congenital infection with the Zika virus attracts attention from public health programs in Brazil, but until now the degree of correlation of ZIKV with auditory impairments are still little known due to the scarcity of studies in this area. During neonatal hearing screening, it has been found that 22.8% of infants infected with ZIKV had altered responses in at least one ear; at re-test, auditory alterations had decreased to 11.4% [8]. ABR tests showed that sensorineural hearing loss was present in 5.8% of the infants.

Research has set out three clinical scenarios in possible maternal exposure to ZIKV: (i) infants with clinical findings consistent with ZIKV congenital syndrome, regardless of maternal test results; (ii) infants without congenital clinical findings of ZIKV who were born from mothers with laboratory evidence of possible ZIKV infection; and (iii) infants without clinical findings consistent with ZIKV congenital syndrome who were born to mothers without laboratory evidence of possible ZIKV infection. Under conditions (i) and (ii), infants should be monitored more closely and undergo more testing, whereas in condition (iii) additional tests are not indicated [28,29].

In the present study, the infant fits into the first scenario described above. This is confirmed by Soares de Oliveira-Szejnfeld et al. [7], whose radiological findings found evidence of calcifications at gray–white matter junctions in patients with ZIKV. Moreover, delayed cortical development (ranging from a mildly simplified gyral pattern to abnormalities such as lissencephaly, pachygyria, or malformations

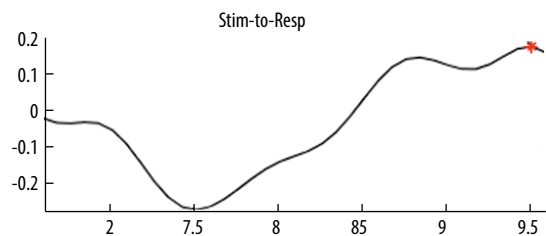


Figure 4. Correlogram (stimulus and response) for the child at age 23 months

of cortical development) have only been found to date in ZIKV-positive patients.

Any infant with ZIKV should have coordinated assessments by multiple specialists in the first month of life. However, in the present case, the economic and social conditions of the care-giver prevented the follow-up that ideally should include evaluations of hearing, feeding, growth, neural development, and endocrine function.

In the present study, the infant had not undergone neonatal hearing screening. American recommendations are that if an infant undergoes neonatal hearing screening, such as an otoacoustic emissions test, it should be complemented with ABR screening before the first month of life. In 2016, recommendations were made that if an infant underwent a normal hearing screen, a new ABR should be performed at 4–6 months of age [30]; however, this recommendation does not apply in the present case since there is no data on the existence of late hearing loss in infants with ZIKV. Thus, infant monitoring will depend on the clinical findings of each case.

Due the economic condition of the family and the delicate and complex health condition of the infant, the audiological evaluation was performed only at 23 months of age. Commentaries on the findings of the audiological exams are set out below.

(i) Tympanometry and acoustic reflex showed no conductive impairment in either ear (both had type A curves) but there was an absence of ipsilateral and contralateral acoustic reflexes. The acoustic reflex is involved in giving a sense of sound direction (due to binaural interaction), decreasing background noise, and improving speech intelligibility [31,32]. An absence of the acoustic reflex is therefore a preliminary indication of alterations in the auditory system which might lead to major communication deficits.

(ii) Absence of evoked otoacoustic emissions (OAEs and DPOAEs) in both ears points to poor outer hair cell function, although absence of emissions can also be caused by alterations in the middle ear. However, normal tympanometry responses rule out conductive hearing loss. Involvement of the outer hair cells in both ears has already been described in other studies [33]. Other studies corroborate that congenital Zika virus infection causes sensorineural hearing loss [34].

(iii) The ABR showed no response in either ear, indicating that there was a compromised brainstem region. Click ABR represents the sequential activation of structures along the auditory trajectory from the auditory nerve to the brainstem, so the altered responses reflect dysfunction of these structures. In the present case, ABR responses evidenced hearing pathway impairment in both ears up to the brainstem. The indications available from the use of this type of assessment tool are valuable and are well suited for study of infants affected with ZIKV. ABR use should be encouraged, as it is an objective instrument, noninvasive, and effective in identifying hearing loss as well as brain lesions. Nevertheless, in Brazil there is still no consensus, or even a protocol, that sets out how to perform this procedure in children with ZIKV, even though it is well understood that infants with risk of hearing impairment require early diagnosis and monitoring of hearing and language impairments. As a related example, infants with congenital toxoplasmosis infection generally have much poorer ABR responses compared to healthy infants. Cases of toxoplasmosis have similar impairments as in infants with ZIKV – intracranial calcifications and hydrocephalus [27,35].

(iv) The FFR showed the presence of all components but with prolonged latency and reduced amplitude. The FFR responses indicate alterations in speech perception, with a reduction in the number of neurons devoted to coding speech. Good correlations are normally expected between a stimulus and the

elicited electrophysiological response, and the low correlation observed in the present study points to a deficiency in the activation of speech-responsive neurons. This was apparent in the correlogram, which had a value of 0.19 whereas a value of around 1.0 is considered normal. In the present study, it was possible to see low synchronization of populations of neurons in the correlogram and FFR responses. Synchronization is important for adequate learning development and is a fundamental operating principle of brainstem function, specifically in spectral and temporal coding. The FFR has been shown to be an electrophysiological instrument capable of monitoring the neural development of speech sounds in a fast, reliable, and objective manner, and has often been recommended as a way of detecting an infant's ability to acquire language, speech, and learning at an early stage [36–39]. In a recent study, researchers have demonstrated that infants with congenital toxoplasmosis have disorganized neural coding of speech. If the responses to FFRs can be verified, they could be a way of detecting this pathology, providing support for the differential diagnosis and therapy of infants with the condition. However, since there is no preexisting data on FFR in cases of CZS, comparisons with other cases cannot be made at this stage.

As recommended by American guidelines, when auditory abnormalities are suspected it is essential that the infant be immediately referred to a specialist audiologist for a more reliable diagnosis [40]. Babies with laboratory evidence of congenital Zika virus infection need to be periodically monitored for auditory issues [41]. In addition to standard audiological tests, it is recommended that the infant's hearing be monitored with complementary procedures such as the frequency-specific ABRs and the auditory brainstem steady-state response.

The long-term prognosis for children with congenital Zika virus infection is not yet known. Consequently, physicians and service providers who are close to these infants should seek to identify any abnormality at an early stage and begin a hearing rehabilitation program. In this way, the child's hearing abilities can be improved, increasing their chances of developing good speech and language skills.

Conclusions

Few studies have analyzed hearing responses in individuals with congenital Zika virus syndrome (CZS). The current study appears to be the only one that has investigated frequency following responses in an individual with the condition. The present case study increases our knowledge of the effect of CZS on the auditory nervous system, revealing a number of diminished responses. This case reinforces the recommendation that ZIKV be included as an indicator for risk of hearing loss.

References

1. Calvet G, Aguiar R, Melo A, et al. Detection and sequencing of Zika virus from amniotic fluid of fetuses with microcephaly in Brazil: a case study. *Lancet Infect Dis*, 2016; 16: 653–60.
2. Oliveira, Melo A, Malinger G, Ximenes R, Szejnfeld P, Alves Sampayo S, et al. Zika virus intrauterine infection causes fetal brain abnormality and microcephaly: tip of the iceberg? *Ultrasound Obstet Gynecol*, 2016; 47:6–7.
3. Brito C. Zika virus: a new chapter in the history of medicine. *Acta Med Port*, 2015; 28: 679–80.
4. Araújo Td, Ximenes R, Miranda-Filho D, Souza W, Montarroyos U, Melo A, et al. Association between microcephaly, Zika virus infection, and other risk factors in Brazil: final report of a case–control study. *Lancet Infect Dis*. 2018; 18: 328–36.

5. Stirnemann J, Villar J, Salomon LJ, et al. International estimated fetal weight standards of the INTERGROWTH-21st Project. *Ultrasound Obstet Gynecol*, 2017; 49(4): 478–86.
6. Melo A, Aguiar R, Amorim M, Arruda M, Melo F, Ribeiro S, et al. Congenital zika virus infection: beyond neonatal microcephaly. *JAMA Neurol*, 2016; 73: 1407–16.
7. Soares de Oliveira-Szejnfeld P, Levine D, Melo A, et al. Congenital brain anomalies and zika virus: what the radiologist can expect to see prenatally and postnatally. *Radiology*, 2016; 281: 203–18.
8. Leal M, Muniz L, Ferreir aT, et al. Hearing loss in infants with microcephaly and evidence of congenital zika virus infection: Brazil, November 2015–May 2016. *MMWR Morb Mortal Wkly Rep*, 2016; 65(34): 917–9.
9. Ventura C, Maia M, Travassos S, et al. Risk factors associated with the ophthalmoscopic findings identified in infants with presumed zika virus congenital infection. *JAMA Ophthalmol*, 2016; 134: 912–8.
10. Pessoa A, Van der Linden V, Yeargin-Allsopp M, Carvalho M, Ribeiro E, Van Naarden Braun K, et al. Motor abnormalities and epilepsy in infants and children with evidence of congenital zika virus infection. *Pediatrics*, 2018;141:S167–S179.
11. Duffy M, Chen T, Hancock W, Powers A, Kool J, Lanciotti R, et al. Zika virus outbreak on Yap Island, Federated States of Micronesia. *N Engl J Med*, 2009; 360: 2536–43.
12. Lessler J, Chaisson L, Kucirka L, Bi Q, Grantz K, Salje H. Assessing the global threat from Zika virus. *Science*, 2016; 353.
13. Pereira JP, Maykin MM, Vasconcelos Z, Avvad-Portari E, Zin AA, Tsui I, et al. The role of amniocentesis in the diagnosis of congenital Zika syndrome. *Clin Infect Dis*, 2019; 69(4): 713–6.
14. Musso D, Roche C, Nhan T, Robin E, Teissier A, Cao-Lormeau V. Detection of Zika virus in saliva. *J Clin Virol*, 2015; 68: 53–5.
15. Jerger J. Clinical experience with impedance audiometry. *Arch Otolaryngol*, 1970; 92(4): 311–24.
16. Jasper HH. The ten–twenty electrode system of the International Federation. *Electroencephalogr Clin Neurophysiol*, 1958; 10: 371–75.
17. Gorga MP, Reiland JK, Beauchaine KA, Worthington DW, Jesteadt W. Auditory brainstem responses from graduates of an intensive care nursery: normal patterns of response. *J Speech Hear Res*, 1987; 30(3): 311–8.
18. Gorga MP, Kaminski JR, Beauchaine KL, Jesteadt W, Neely ST. Auditory brainstem responses from children three months to three years of age: normal patterns of response II. *J Speech Hear Res*, 1989; 32: 281–8.
19. Sanfins MD, Borges LR, Ubiali T, Donadon C, Hein TAD, Hatzopoulos S, et al. Speech-evoked brainstem response in normal adolescent and children speakers of Brazilian Portuguese. *Int J Pediatr Otorhinolaryngol*, 2016 Nov; 90: 12–9.
20. Johnson KL, Nicol T, Zecker SG, Kraus N. Developmental plasticity in the human auditory brainstem. *J Neurosci*, 2008; 28(15): 4000–7.
21. Ahadi M, Pourbakht A, Jafari AH, Jalaie S. Effects of stimulus presentation mode and subcortical laterality in speech-evoked auditory brainstem responses. *Intl J Audiol*, 2014; 53(4): 243–9.
22. Rana B, Barman A. Correlation between speech-evoked auditory brainstem responses and transient evoked otoacoustic emissions. *J Laryngol Otol*, 2011; 125(9): 911–6.
23. Wagner R, Torgesen J, Rashotte C. Development of reading-related phonological processing abilities: new evidence of bidirectional causality from a latent variable longitudinal study. *Devel Psychol*, 1994; 30(1): 73–87.
24. Karawani H, Banai K. Speech-evoked brainstem responses in Arabic and Hebrew speakers. *Intl J Audiol*, 2010; 49(11): 844–9.
25. Song JH, Nicol T, Kraus N. Test–retest reliability of the speech-evoked auditory brainstem response. *Clin Neurophysiol*, 2011; 122(2): 346–55.
26. Russo N, Nicol T, Musacchia G, Kraus N. Brainstem responses to speech syllables. *Clin Neurophysiol*, 2004; 115: 2021–30.
27. American Academy of Pediatrics, Joint Committee on Infant Hearing. Year 2007 position statement: principles and guidelines for early hearing detection and intervention programs. *Pediatrics*, 2007; 120: 898–921.
28. Scharf R, Scharf G, Stroustrup A. Developmental milestones. *Pediatr Rev*, 2016; 37: 25–37.
29. Council on Children with Disabilities. Identifying infants and young children with developmental disorders in the medical home: an algorithm for developmental surveillance and screening. *Pediatrics*, 2006; 118: 405–20.
30. Russell K, Oliver S, Lewis L, et al. Update: interim guidance for the evaluation and management of infants with possible congenital Zika virus infection—United States, August 2016. *MMWR Morb Mortal Wkly Rep*, 2016; 65: 870–8.
31. Simmons F. Perceptual theories of middle ear muscle function. *Ann Otol Rhinol Laryngol*, 1964; 73: 724–39.
32. Wormald P, Rogers C, Gatehouse S. Speech discrimination in patients with Bell’s palsy and a paralysed stapedius muscle. *Clin Otolaryngol Allied Sci*, 1995; 20: 59–62.
33. Leite RFP, Santos MSA, Ribeiro EM, Pessoa ALS, Lewis DR, Giacheti CM, et al. Hearing screening in children with congenital zika virus syndrome in Fortaleza, Ceará, Brazil, 2016. *Epidemiol Serv Saúde*, 2018 Nov 8; 27(4): e2017553.
34. Leal MC, Muniz LF, Caldas Neto SS, Van der Linden V, Ramos RCF. Sensorineural hearing loss in a case of congenital Zika virus. *Braz J Otorhinolaryngol*, 2016 Jun-Aug; 86(4): 513–5.
35. Khan K, Khan W. Congenital toxoplasmosis: An overview of the neurological and ocular manifestations. *Parasitol Int*, 2018; 67: 195–21.
36. Sanfins MD, Garcia MV, Biaggio EPV, Skarzynski PH. The frequency-following response: evaluations in different age groups. In: Hatzopoulos S, Ciorba A, Skarzynski PH. *Human Auditory System: Basic features and updates on audiological diagnosis and therapy*. Croatia: IntechOpen; 2019. doi: 10.5772/intechopen.85076.
37. Banai K, Amitay S. The effects of stimulus variability on the perceptual learning of speech and non-speech stimuli. *PLoS One*, 2015; 10(2): e0118465.
38. Anderson S, Parbery-Clark A, White-Schwoch T, Kraus N. Development of subcortical speech representation in human infants. *J Acoust Soc Am*, 2015; 137: 3346–55.
39. Sanfins MD, Skarzynski PH, Colella-Santos MF. Speech-evoked brainstem response. In: Hatzopoulos S, editor. *Advances in Clinical Audiology*. Croatia: IntechOpen; 2017. doi: 10.5772/66206.
40. American Academy of Pediatrics, Joint Committee on Infant Hearing. Year 2007 position statement: principles and guidelines for early hearing detection and intervention programs. *Pediatrics*, 2007; 120: 898–921.
41. Kuo D, Houtrow A, Arango P, Kuhlthau K, Simmons J, Neff J. Family-centered care: current applications and future directions in pediatric health care. *Matern Child Health J*, 2012; 16: 297–305.