

ELECTRO-NATURAL STIMULATION (ENS) IN PARTIAL DEAFNESS TREATMENT: A CASE STUDY

Henryk Skarżyński^{1,2}, Artur Lorens², Piotr Henryk Skarżyński^{1,3,4}

¹ Oto-Rhino-Laryngology Surgery Clinic, Institute of Physiology and Pathology of Hearing, Warsaw/Kajetany, Poland

² World Hearing Center, Institute of Physiology and Pathology of Hearing, Warsaw/Kajetany, Poland

³ Heart Failure and Cardiac Rehabilitation Department of the Medical University of Warsaw, Warsaw, Poland

⁴ Institute of Sensory Organs, Warsaw/Kajetany, Poland

Corresponding author: Piotr H. Skarżyński, World Hearing Center, Institute of Physiology and Pathology of Hearing, Mochnackiego 10 Str., 02-042 Warsaw, Poland, e-mail: p.skarzynski@inz.waw.p

Abstract

Background: There is a significant group of elderly patients whose hearing impairment is characterized by normal or slightly elevated thresholds in the low and mid frequency bands (below 1500 Hz) with nearly total deafness in the high frequency range. These patients very often remain beyond the scope of effective treatment by hearing aids.

Case Report: This study presents the case of a 75-year-old patient with good hearing in the range 125–1500 Hz and deafness at other frequencies. An implant was used to restore hearing at high frequencies, while preserving low and mid frequency acoustic hearing in the implanted ear. This can be described as electro-natural stimulation (ENS) of the inner ear.

Conclusions: The results demonstrate that low and mid frequency hearing (up to 1500 Hz) can be preserved using the round window surgical technique. A substantial improvement in speech discrimination was also observed when electrical stimulation on one side was combined with acoustic stimulation on both sides. There is scope to extend qualifying criteria for cochlear implantation to include elderly patients suitable for ENS.

Keywords: Partial Deafness Treatment • hearing preservation • electric stimulation • cochlear implants

LA ESTIMULACIÓN ELECTRO-NATURAL (ENS) EN EL TRATAMIENTO DE LA SORDERA PARCIAL: UN ESTUDIO DE CASO

Resumen

Introducción: Hay un gran grupo de pacientes de edad avanzada cuya pérdida auditiva se caracteriza por los umbrales de audición normales o un poco elevados en las frecuencias bajas y medias (por debajo de 1500 Hz), combinado con una sordera casi total en el rango de las frecuencias altas. Muy a menudo, no se puede ayudar al paciente efectivamente con los audífonos.

Caso clínico: Este trabajo presenta un caso de una paciente de 75 años de edad, con buena audición en el rango de 125 a 1500 Hz y la sordera en las otras frecuencias. Fue usado un implante para restablecer la audición en el rango de las frecuencias altas. La audición acústica fue guardada en el oído implantado en las frecuencias bajas y medias. Esta situación se puede describir como un caso de estimulación electro-natural (ENS) del oído interno.

Conclusión: Los resultados muestran que es posible guardar la audición en las frecuencias bajas y medias (1500 Hz) utilizando una técnica quirúrgica con el acceso por la ventana redonda. Fue observado una mejora significativa en los resultados de reconocimiento de voz después de aplicar la estimulación eléctrica en un oído combinado con la estimulación acústica de cada oreja. Por lo tanto, parece posible extender los criterios de elegibilidad para el implante coclear incluyendo los pacientes de edad avanzada con indicaciones para la ENS.

Palabras clave: tratamiento de la sordera parcial • conservación de la audición • estimulación eléctrica • implantes cocleares

ЭЛЕКТРО-НАТУРАЛЬНАЯ СТИМУЛЯЦИЯ (ENS) ПРИ ЛЕЧЕНИИ ЧАСТИЧНОЙ ГЛУХОТЫ: ИЗУЧЕНИЕ СЛУЧАЯ

Изложение

Введение: Существует значительная группа пациентов пожилого возраста, нарушение слуха которых характеризуется наличием нормальных либо незначительно увеличенных порогов слышимости на низких и средних

частотах (ниже 1500 Гц) в сочетании с практически полной глухотой на высоких частотах. Очень часто таким пациентам невозможно эффективно помочь, используя слуховые аппараты.

Описание случая: Данная работа представляет случай 75-ти летнего пациента с хорошим слухом в пределах 125–1500 Гц и глухотой на остальных частотах. Был применен имплант с целью восстановления слуха на высоких частотах, с сохранением в имплантированном ухе акустического слуха в пределах низких и средних частот. Этот пример можно описать как случай электро-натуральной стимуляции (ENS) внутреннего уха.

Итоги: Результаты показывают, что возможно сохранить слух на низких и средних частотах (до 1500 Гц) с использованием хирургической техники подхода через круглое окно. Было замечено значительное улучшение результатов разборчивости речи после применения электростимуляции с одной стороны в сочетании с акустической стимуляцией обеих ушей. Поэтому представляется возможным дальнейшее расширение критериев квалификации к вживлению кохлеарного импланта, которые будут распространяться на пациентов пожилого возраста с показаниями к ENS.

Ключевые слова: лечение частичной глухоты • сохранение слуха • электростимуляция • кохлеарные импланты

STYMULACJA ELEKTRO-NATURALNA (ENS) W LECZENIU CZĘŚCIOWEJ GŁUCHOTY: STUDIUM PRZYPADKU

Streszczenie

Wstęp: Istnieje znaczna grupa pacjentów w podeszłym wieku, których niedosłuch charakteryzuje się występowaniem normalnych lub nieznacznie podwyższonych progów słyszenia w zakresie niskich i średnich częstotliwości (poniżej 1500 Hz) w połączeniu z niemal całkowitą głuchotą w zakresie wysokim częstotliwości. Bardzo często pacjentem tym nie można skutecznie pomóc stosując aparaty słuchowe.

Opis przypadku: Niniejsza praca prezentuje przypadek 75-cio letniego pacjenta z dobrym słuchem w zakresie 125–1500 Hz i głuchotą na pozostałych częstotliwościach. Zastosowano implant w celu przywrócenia słuchu w zakresie wysokich częstotliwości, z zachowaniem w uchu implantowanym słuchu akustycznego w zakresie niskich i średnich częstotliwości. Sytuację tą można opisać jako przypadek stymulacji elektro-naturalnej (ENS) ucha wewnętrznego.

Wnioski: Wyniki pokazują, że możliwe jest zachowanie słuchu na niskich i średnich częstotliwościach (do 1500 Hz) z zastosowaniem techniki chirurgicznej dojścia przez okienko okrągłe. Zauważono znaczną poprawę wyników rozpoznawania mowy po zastosowaniu stymulacji elektrycznej po jednej stronie z połączeniem z obu uszną stymulacją akustyczną. Możliwe wydaje się zatem dalsze rozszerzenie kryteriów kwalifikacji do wszczepienia implantu ślimakowego i objęcie nimi starszych pacjentów ze wskazaniami do ENS.

Słowa kluczowe: leczenie częściowej głuchoty • zachowanie słyszenia • stymulacja elektryczna • implanty ślimakowe

Background

Normal or socially satisfactory hearing without the need for acoustic amplification at low and medium frequencies can coexist with profound hearing loss or total deafness in the high frequency range. This type of partial deafness can be diagnosed and treated at any age [1–10]. The biggest group of people with partial deafness of this type are senior citizens. Indeed among males 65 years and older, this type of hearing loss is the most prevalent chronic condition of aging and among older females it is the fourth-most prevalent condition (after arthritis, cardiovascular disease, and visual impairment) [11].

Typically, the profile of the hearing loss of 65-year-old subjects comprises a plateau below 1.5 kHz at a level between 10 and 40 dB, together with a sloping loss at higher frequencies [12]. The only solution to improve hearing is to complement normal hearing at low and mid frequencies (below 1500 Hz) with electric stimulation using a cochlear

implant. This arrangement can be described as electro-natural stimulation (ENS) of the inner ear.

In previous reports we have demonstrated the efficacy of applying electric stimulation to totally (or almost totally) inactive regions of the inner ear using a cochlear implant, thereby complementing the low-frequency preserved hearing. It has been called partial deafness treatment – electric complementation (PDT-EC) [13,14]. In the conception introduced by Skarżyński in 2002 it dealt with frequencies up to 500 Hz [13] and represented a significant breakthrough, extending the previously accepted indications for cochlear implantation. The underlying theory has been subsequently developed, and PDT-EC was thoroughly described and documented in 2010 [15,16] (see Figure 1).

In our terminology, ‘partial deafness’ refers to situations where part of the inner ear remains fully efficient (or partially efficient and requires acoustic amplification), so that some residual hearing, even if non-functional, is preserved.

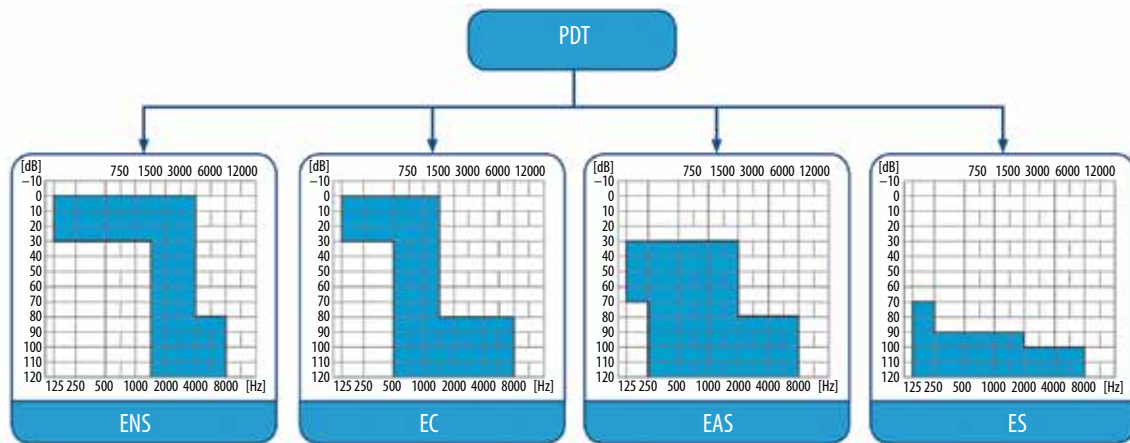


Figure 1. Skarżyński’s original partial deafness conception with the addition of electro-natural stimulation (ENS)

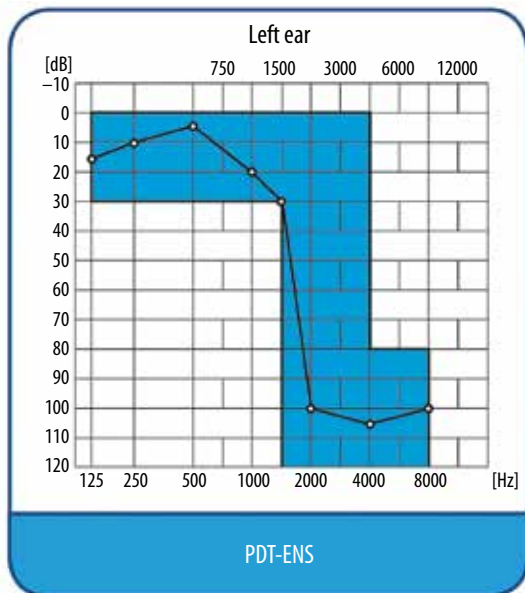


Figure 2. Patient’s pre-operative hearing results based on pure tone audiometry covering the area of electro-natural stimulation (ENS) in the inner ear

At the same time, another part of the ear, usually in the range of medium and high frequencies, may be totally deaf (or hearing loss may be of such a degree that hearing cannot be restored by means of acoustic amplification using classic hearing aids or middle ear implants) [17–20].

In 2013, Skarżyński et al. [21] refined this approach of partial deafness treatment by adding a new method of assessing pre-operative hearing preservation.

The aim of this report is to present the treatment results of an adult with a hearing disorder diagnosed as partial deafness, in whom the natural hearing was complemented by means of electric stimulation in the frequency range above 1500 Hz. In this case the cochlear implant is used as electro-natural stimulation (ENS). This represents a new step forward, demonstrating the possibilities of extending

current indications for cochlear implantation in partial deafness.

Case description

The case was a 75-year-old patient with a fully efficient hearing in the frequency range of 125–1500 Hz and deafness at other frequencies (Figure 2). The hearing loss was bilateral, diagnosed as an acquired and progressive dysfunction. Its specific etiology has not been determined.

Since the patient needed only complementation of natural low and medium frequency hearing, the implantation presented a large challenge to the surgeon because the procedure needed to preserve pre-operative hearing. At the same time, the surgeon was aware that if there were further deterioration of hearing, implantation of at least one ear may be necessary anyway. The decision to use a cochlear implant on this patient was based on their unsatisfactory level of speech understanding in spite of the relatively high level of extant natural hearing. Surgery at this relatively early stage gave the patient the opportunity to achieve better and quicker improvement in post-operative hearing rehabilitation. The surgery was performed in accordance with the 6-step surgical procedure developed by Skarżyński [13,19]:

- Step 1:* Conservative antromastoidotomy, preceded by harvesting a bone chip from the mastoid cortex, which is later used to close the middle ear space;
- Step 2:* Typical posterior tympanotomy with the exposure of the round window;
- Step 3:* Puncture and central incision of the round window membrane;
- Step 4:* Careful insertion, at first by hand and then with forceps, of a flexible active electrode (of the Med-El Flex EAS type) through the round window into scala tympani to a depth of 18 mm;
- Step 5:* Fixation of the electrode in the round window niche with tissue glue and a piece of fascia;
- Step 6:* Fixation of the internal part of the implant into a drilled well, closing the mastoid cavity with the bone chip harvested at the beginning of the procedure, and suturing the incision.

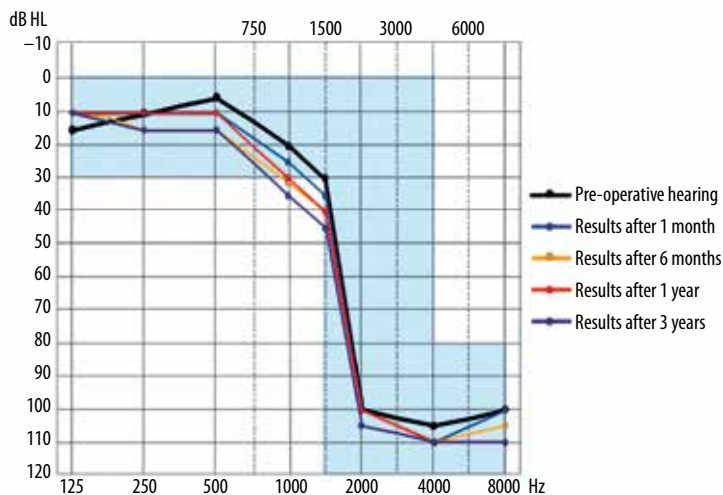


Figure 3. Pre-operative hearing preservation results after 1 month, 6 months, 1 year, and 3 years

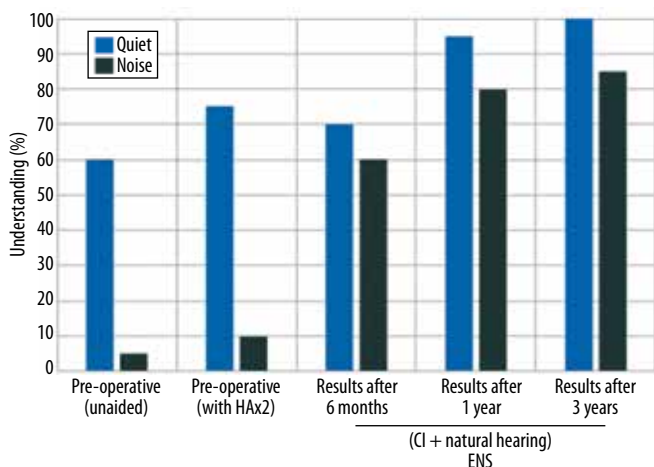


Figure 4. Speech understanding in quiet and in noise (monosyllabic word test)

In a 3-year follow-up period, there has been an evaluation of 1) pre-operative hearing preservation in both the operated and non-operated ear; and 2) improvements in hearing rehabilitation. The results of pre-operative hearing preservation were assessed according to the scale of Skarżyński et al. [21]. Figure 3 presents its level after 1 month, 6 months, 1 year, and 3 years.

The surgical procedure as described by Skarżyński et al. [13,19] has permitted the use of a cochlear implant to surgically treat partial deafness with electric complementation of natural hearing at low and medium frequencies. It has fully preserved hearing during a 3-year follow-up (complete preservation according to the scale [21]). Its success demonstrates how current indications for cochlear implantation can be widened to include a new target group of patients. It is pleasing to note very good long-term preservation of pre-operative hearing, both in the operated and non-operated ears. There was only 5 dB increase in the pure tone average (PTApost) measured post-operatively in the implanted over 3 years. The slight deterioration of hearing observed in both ears is probably related to the patient's standing progressive hearing deterioration of unknown etiology. Figure 4 presents the results

of speech understanding in quiet and noise in subsequent follow-up periods.

Over a period of 12 months, monosyllabic word recognition increased from 60 to 100% under quiet conditions and from 5 to 85% under noisy conditions.

Our case showed a large increase in hearing performance over the first 12 months after activation of the implant, particularly performance under noise. This improvement was due to ENS rather than electric-only stimulation, since acoustic low frequency cues are necessary for good levels of speech discrimination in noise [22]. The performance plateaued after 12 months, both under quiet and noisy conditions, with only a 5 percentage point increase in scores beyond this time. A slight deterioration in hearing over 3 years did not diminish the benefits of ENS, since speech discrimination was stable after 12 months.

By calculating the percentage change of PTApost according to equation [21], it can be seen that only 9% of total hearing was lost in the 3 years after surgery. If 91% hearing remains, it can be inferred that most of the low frequency cues important to speech discrimination

were still available and giving an ENS benefit 3 years after implantation. An alternative explanation is a long-term learning effect, with small long-term increases in speech discrimination between 12 months and 3 years. Prolonged ENS might promote brain plasticity and help the brain learn to make use of the peripheral inputs provided by ENS.

The results demonstrate long-term preservation of pre-operative hearing, confirming the appropriateness of the decision to operate, the choice of surgical method, and the use of the ENS mode. The case indicates that there is a real possibility of extending the indications for cochlear implantation to include patients with various levels of partial deafness, and even to cases of age-related presbycusis, which will become a growing therapeutic problem. This is

in line with results of the study done by Moran et al who conclude that postlingually deafened adults with sloping hearing loss have the potential to gain significant benefit from cochlear implants [23].

Conclusions

1. Long-term follow-up of the implanted patient with partial deafness has demonstrated that indications for cochlear implantation can be extended to people with serviceable pre-operative hearing at low and medium frequencies.
2. The long-lasting results and positive effects of pre-operative hearing preservation confirm the choice of a surgical strategy using a round-window approach and a maximally flexible electrode.

References:

1. Blamey P, Artieres F, Başkent D, Bergeron F, Beynon A, Burke E et al. Factors affecting auditory performance of postlinguistically deaf adults using cochlear implants: an update with 2251 patients. *Audiol Neurootol*, 2012; 18(1): 36–47.
2. Dorman MF, Gifford RH. Combining acoustic and electric stimulation in the service of speech recognition. *Int J Audiol*, 2010; 49(12): 912–9.
3. Gifford RH, Dorman MF, Skarżyński H, Lorens A, Polak M, Driscoll CL et al. Cochlear implantation with hearing preservation yields significant benefit for speech recognition in complex listening environments. *Ear Hear*, 2013; 34(4): 413–25.
4. Helbig S, Baumann U, Hey C, Helbig M. Hearing preservation after complete cochlear coverage in cochlear implantation with the free-fitting FLEXSOFT electrode carrier. *Otol Neurotol*, 2011; 32(6): 973–9.
5. Lorens A, Skarżyński H. Technologia implantów ślimakowych. *Nowa Audiofonologia*, 2012; 1(3): 18–23.
6. Lorens A, Zgoda M, Skarżyński H. A new audio processor for combined electric and acoustic stimulation for the treatment of partial deafness. *Acta Otolaryngol*, 2012; 132(7): 739–50.
7. Prentiss S, Sykes K, Staecker H. Partial deafness cochlear implantation at the University of Kansas: techniques and outcomes. *J Am Acad Audiol*, 2010; 21(3): 197–203.
8. Skarżyński H, Lorens A, D'Haese P, Walkowiak A, Piotrowska A, Śliwa L et al. Preservation of residual hearing in children and post-lingually deafened adults after cochlear implantation: an initial study. *ORL J Otorhinolaryngol Relat Spec*, 2002; 64(4): 247–53.
9. Skarżyński H, Lorens A, Matusiak M, Porowski M, Skarżyński PH, James CJ. Partial deafness treatment with the Nucleus straight research array cochlear implant. *Audiol Neurootol*, 2012; 17(2): 82–91.
10. Van de Heyning P, Adunka O, Arauz SL, Atlas M, Baumgartner WD, Brill S et al. Standards of practice in the field of hearing implants. *Cochlear Implants Int*, 2013; 14(Suppl. 2): 1–5.
11. Collins, JG. Prevalence of selected chronic conditions: United States 1990–1992. National Center for Health Statistics. *Vital and Health Statistics*, 1997; 10: 194.
12. Mills JH, Schmiedt RA, Dubno JR. Older and wiser, but losing hearing nonetheless. *Hear Health*, 2006; 12–17.
13. Skarżyński H, Lorens A, Piotrowska A. A new method of partial deafness treatment. *Med Sci Monit*, 2003; 9(4): CS20–24.
14. Skarżyński H, Lorens A, Piotrowska A, Anderson I. Partial deafness cochlear implantation in children. *Int J Pediatr Otorhinolaryngol*, 2007; 71: 1407–13.
15. Skarżyński H, Lorens A, Piotrowska A, Skarżyński PH. Hearing preservation in partial deafness treatment. *Med Sci Monit*, 2010; 16(11): CR555–62.
16. Skarżyński H, Lorens A. Partial deafness treatment. *Cochlear Implant Int*, 2010; 11(Suppl 1): 29–41.
17. Skarżyński H, Lorens A, Zgoda M, Piotrowska A, Skarżyński PH, Szkielkowska A. Atraumatic round window deep insertion of cochlear electrodes. *Acta Oto-Laryngologica*, 2011; 131(7): 740–9.
18. Skarżyński H, Lorens A, Matusiak M, Porowski M, Skarżyński PH, James CJ. Cochlear implantation with the Nucleus slim straight electrode in subjects with residual low-frequency hearing. *Ear Hear*, 2014; 35(2): e33–43.
19. Skarżyński H, Matusiak M, Piotrowska A, Skarżyński PH. Surgical techniques in partial deafness treatment. *J Hear Sci*, 2012; 2(3): 9–13.
20. Skarżyński H. Ten years' experience with a new strategy of partial deafness treatment. *J Hear Sci*, 2012; 2(2): 11–18.
21. Skarżyński H, van de Heyning P, Agrawal S, Arauz SL, Atlas M, Baumgartner W et al. Towards a consensus on a hearing preservation classification system. *Acta Oto-Laryngologica*, 2013; 133 (Suppl 564): 3–13.
22. Lorens A, Polak M, Piotrowska A, Skarżyński H. Outcomes of treatment of partial deafness with cochlear implantation: a DUET study. *Laryngoscope* 2008; 118(2): 288–94.
23. Moran M, Dowell RC, Umansky A, Briggs RJS, Corbett S. Outcomes for patients with sloping hearing loss given standard cochlear implants. *J Hear Sci*, 2014; 4(3): 9–19.